

Copyright Warning & Restrictions

The copyright law of the United States (Title 17, United States Code) governs the making of photocopies or other reproductions of copyrighted material.

Under certain conditions specified in the law, libraries and archives are authorized to furnish a photocopy or other reproduction. One of these specified conditions is that the photocopy or reproduction is not to be “used for any purpose other than private study, scholarship, or research.” If a user makes a request for, or later uses, a photocopy or reproduction for purposes in excess of “fair use” that user may be liable for copyright infringement,

This institution reserves the right to refuse to accept a copying order if, in its judgment, fulfillment of the order would involve violation of copyright law.

Please Note: The author retains the copyright while the New Jersey Institute of Technology reserves the right to distribute this thesis or dissertation

Printing note: If you do not wish to print this page, then select “Pages from: first page # to: last page #” on the print dialog screen

The Van Houten library has removed some of the personal information and all signatures from the approval page and biographical sketches of theses and dissertations in order to protect the identity of NJIT graduates and faculty.

ABSTRACT

A Review of Acetabular Prostheses for Total Hip Arthroplasty

by
Jennifer Anne Citarella

This study explores the evolution, design, and clinical progress of contemporary prostheses used in orthopaedic reconstruction of the socket of the hip joint. A literature search was performed to study acetabular implants, as used in total hip arthroplasty. The history of the design of these implants is chronicled. Next, the anatomy of the acetabular region and the surgical technique performed to replace the hip socket are presented. A comprehensive discussion of the design features, rationale, and clinical results for commercially available cemented and cementless prostheses follows.

Hydroxyapatite, a bioceramic which has just recently been approved for applications in total hip arthroplasty, is described, the coating process explained, and its clinical effects evaluated. Finally, the abnormal or deficient acetabulum is reviewed. Corrective implants and reconstructive techniques are described.

A REVIEW OF ACETABULAR PROSTHESES
FOR TOTAL HIP ARTHROPLASTY

by
Jennifer Anne Citarella

A Thesis
Submitted to the Faculty of
New Jersey Institute of Technology
in Partial Fulfillment of the Requirements for the Degree of
Master of Science in Biomedical Engineering

Department of Biomedical Engineering

May 1993

APPROVAL PAGE

A Review of Acetabular Prostheses
for Total Hip Arthroplasty

Jennifer Anne Citarella

May 1993

Dr. Rajpal Sodhi, Thesis Advisor
Associate Professor of Mechanical Engineering,
Director of Manufacturing Engineering Programs,
New Jersey Institute of Technology

Dr. Sanchoy Das
Assistant Professor of Industrial and Management Engineering,
New Jersey Institute of Technology

Dr. David Kristol
Professor of Chemistry,
Director and Graduate Advisor of Biomedical Engineering,
Director of the Center for Biomedical Engineering,
New Jersey Institute of Technology

BIOGRAPHICAL SKETCH

Author: Jennifer Anne Citarella

Degree: Master of Science in Biomedical Engineering

Date: May 1993

Undergraduate and Graduate Education:

- Master of Science in Biomedical Engineering
New Jersey Institute of Technology, Newark, NJ, 1993
- Bachelor of Engineering
Stevens Institute of Technology, Hoboken, NJ, 1986

Major: Biomedical Engineering

ACKNOWLEDGMENT

The author wishes to express her appreciation to Dr. Raj Sodhi for his continued support during the development of this work.

Thank you to Dr. David Kristol for his help and understanding throughout the years dedicated to the attainment of the Master of Science degree.

The author is also grateful to Jon Klippel for his persistence in assuring this project would be completed.

TABLE OF CONTENTS

| Chapter | Page |
|--|------|
| 1 INTRODUCTION..... | 1 |
| 2 ANATOMY OF THE ACETABULUM..... | 3 |
| 3 EVOLUTION OF ACETABULAR COMPONENT DESIGN IN TOTAL HIP ARTHROPLASTY..... | 6 |
| 4 SURGICAL TECHNIQUE..... | 10 |
| 4.1 Common Preparation..... | 10 |
| 4.2 Cemented Implant..... | 13 |
| 4.3 Cementless Implant..... | 14 |
| 5 ACETABULAR IMPLANTS..... | 16 |
| 5.1 Cemented All Polyethylene..... | 16 |
| 5.1.1 Longevity of fixation..... | 16 |
| 5.1.2 Design Features..... | 18 |
| 5.1.3 Finite Element Analyses..... | 18 |
| 5.1.4 Effects of Bone Cement..... | 20 |
| 5.1.5 Clinical Results..... | 21 |
| 5.2 Cemented Metal Backed..... | 25 |
| 5.2.1 Finite Element Analyses..... | 25 |
| 5.2.2 Design Features..... | 28 |
| 5.2.3 Clinical Results..... | 28 |
| 5.3 Cementless Components..... | 32 |
| 5.3.1 Design Rationale..... | 32 |
| 5.3.2 Clinical Results..... | 33 |
| 5.3.3 Adjuvant Fixation and Screw Placement..... | 37 |

| | |
|--|----|
| 5.4 Threaded Cup..... | 43 |
| 5.4.1 Design Rationale..... | 43 |
| 5.4.2 Clinical Results..... | 43 |
| 6 HYDROXYAPATITE..... | 47 |
| 6.1 Description..... | 47 |
| 6.2 Processing Factors..... | 48 |
| 6.3 Clinical Results..... | 49 |
| 7 ACETABULAR DEFICIENCIES..... | 51 |
| 7.1 Classification Systems/Operative Techniques..... | 51 |
| 7.2 Protrusio..... | 55 |
| 7.2.1 Protrusio Shell..... | 55 |
| 7.2.2 Surgical Technique | 57 |
| 7.2.3 Finite Element Analysis..... | 58 |
| 7.3 Bone Grafting..... | 59 |
| 7.3.1 Types..... | 59 |
| 7.3.2 Clinical Results..... | 61 |
| 7.3.3 Revision..... | 63 |
| 8 CONCLUSION..... | 66 |
| APPENDIX Anatomic Positions and Directions..... | 68 |
| REFERENCES..... | 69 |
| GLOSSARY..... | 74 |

LIST OF TABLES

| Table | Page |
|--|------|
| 1 Torsional strength of anchoring hole patterns... Facing | 16 |
| 2 Finite element models tested by Carter, <i>et al</i> | 25 |
| 3 Parameters of Harris and Dorr studies..... | 29 |
| 4 Scheme for treating acetabular defects..... Facing | 55 |

LIST OF FIGURES

| Figure | Page |
|--|-----------|
| 1 Orientation of Acetabulum in Pelvis..... | Facing 3 |
| 2 Acetabulum..... | Facing 3 |
| 3 Mold Arthroplasty..... | Facing 7 |
| 4 Aufranc's true arc Vitallium mold arthroplasty... | Facing 8 |
| 5 Hip-socket Arthroplasty..... | Facing 8 |
| 6 The Charnley low-friction arthroplasty..... | Facing 9 |
| 7 Capsulotomy..... | Facing 11 |
| 8 Dislocation of hip..... | Facing 11 |
| 9 Reaming of the acetabulum..... | Facing 12 |
| 10 Drilling of cement anchoring holes..... | Facing 13 |
| 11 Implantation of cemented prosthesis..... | Facing 13 |
| 12 Drill guide instrumentation..... | Facing 14 |
| 13 Implantation of cementless prosthesis..... | Facing 15 |
| 14 Cement anchoring hole patterns..... | Facing 17 |
| 15 Cement pressurizing device..... | Facing 17 |
| 16 All-polyethylene acetabular implant..... | Facing 18 |
| 17 Von Mises' stresses..... | Facing 19 |
| 18 Schematic section of modelled acetabular cup fixation system..... | Facing 21 |
| 19 Huiskes' "necrosis map"..... | Facing 21 |
| 20 Correlation between the depth of socket wear and the incidence of socket migration..... | Facing 23 |
| 21 Cemented metal-backed prosthesis..... | Facing 25 |
| 22 Von Mises' contour plots as percentage of yield stress for non-metal-backed components.. | Facing 26 |

| | | |
|----|--|-----------|
| 23 | Von Mises' contour plots as percentage of yield stress for metal-backed components..... | Facing 26 |
| 24 | Cementless acetabular implants..... | Facing 32 |
| 25 | Average intercortical thickness mapped as a percent of acetabular diameter..... | Facing 40 |
| 26 | Safe zones at screw lengths 40% of acetabular diameter for 40, 45, 52, and 57 mm diameter acetabuli..... | Facing 41 |
| 27 | Superior segmental defect..... | Facing 52 |
| 28 | Central cavitary defect..... | Facing 52 |
| 29 | Two views of the Oh-Harris protrusio shell..... | Facing 56 |
| 30 | Heywood technique..... | Facing 57 |

CHAPTER 1

INTRODUCTION

Reconstruction of the hip joint has become eminently successful. Total hip arthroplasty, the surgical procedure in which the ball and socket joint is replaced with metallic and plastic prostheses, is now performed over 120,000 times a year in the United States. Since the pioneering work of surgeon Sir John Charnley, the goal of total hip arthroplasty has remained the same - to obtain a durable, painless, and functional hip in patients affected by severe arthritis and joint disease.

The socket portion of the joint, or acetabulum, is reconstructed with prostheses which are implanted either by cementing the component to the bone, or by fitting the component directly into the socket. Back in the 1960s and 1970s, the orthopaedic community learned, and tried to perfect, the cemented total hip reconstructive procedure. However, with the occurrence of an unacceptable number of failures, alternatives were sought. New cup designs and improved cementation techniques arrived in the late 1970s. Excellent initial fixation and stability between the bone, cement, and implant is readily achieved with cement fixation. Long-term durability, especially in younger patients, is somewhat less reliable.

The other line of investigation led to the elimination of bone cement entirely. One concept was to obtain a mechanical

interlock of bone into the acetabular prosthesis. By the 1980s, components with porous surfaces were introduced with the potential advantage of increased longevity of fixation through bony ingrowth. Another idea was to screw a metal threaded prosthesis into the acetabulum to achieve immediate mechanical fixation for stability.

From the time total hip replacement technology was introduced over thirty years ago, its aim has been to use designs and materials for components which could fully integrate with the human body. Orthopaedic science is closer to this goal now more than ever, and additional progress is on the horizon.

The objective of this study was to perform a comprehensive analysis of socket reconstruction in total hip arthroplasty. With the increasing popularity of this elective surgical procedure, orthopaedists are forced to closely examine implant options and make educated choices on what will give them the best results. To obtain an overall view of the climate surrounding acetabular prostheses, the evolution of these devices was traced, and design philosophies with their associated clinical results were reviewed.

Facing 3

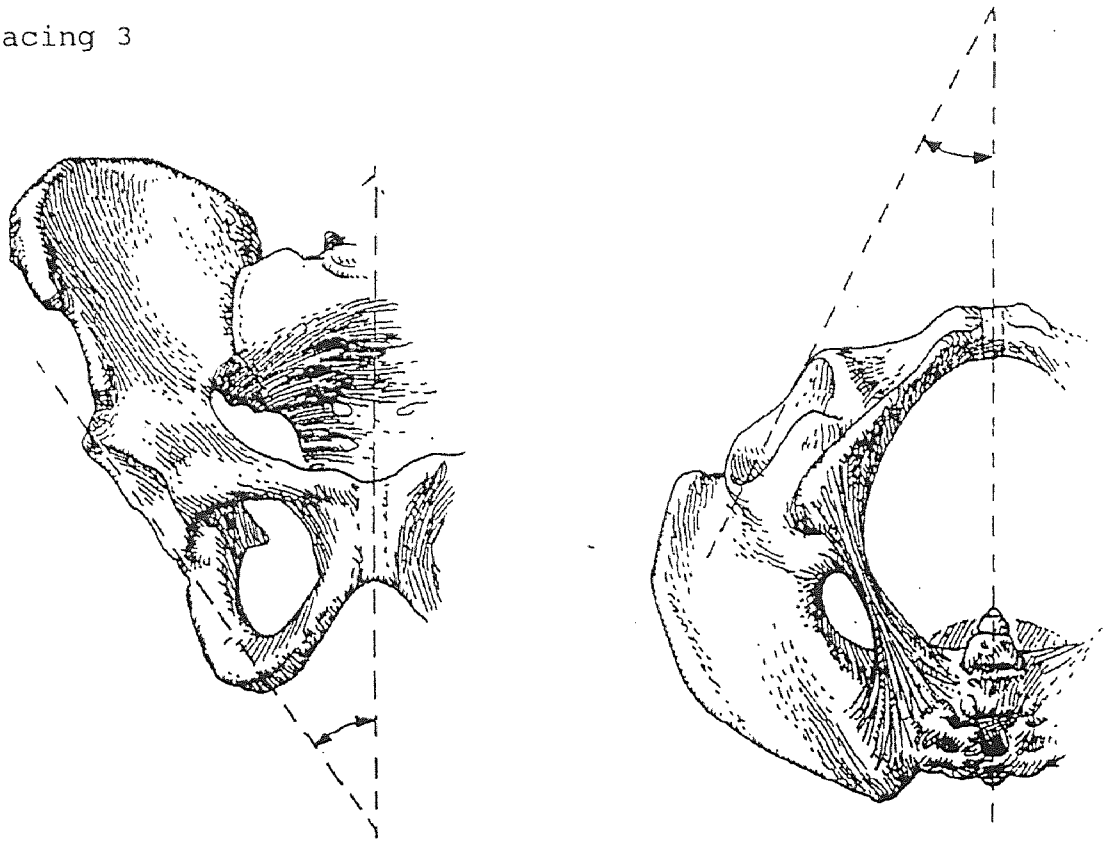


Figure 1 Orientation of Acetabulum in Pelvis [57]

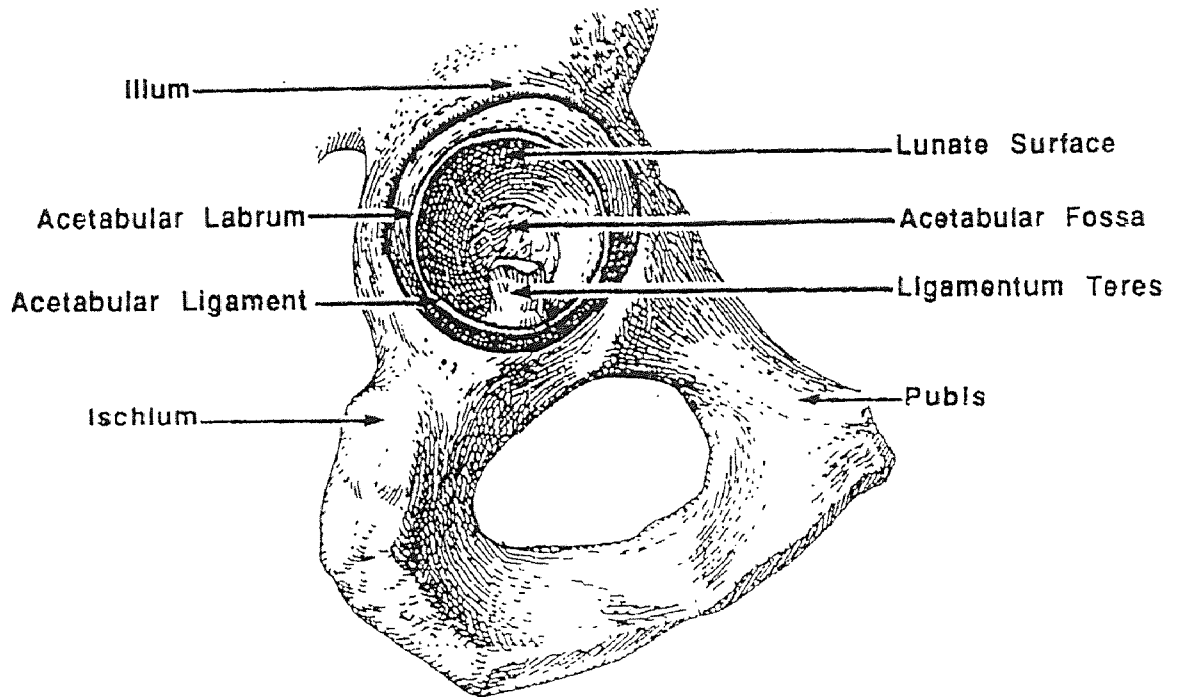


Figure 2 Acetabulum [57]

CHAPTER 2

ANATOMY OF THE ACETABULUM

The acetabulum is the socket portion of the hip joint. It is located at the lateral aspect of the hip where the ilium, ischium, and pubis unite to form a deep socket. The bony rim of the acetabulum does not align with the vertical plane. Rather, it is tilted downward, approximately 35 degrees off of vertical, in a configuration known as lateral opening. Thus the superior rim of the acetabulum is tilted toward the lateral, and the inferior rim is tilted toward the medial.

The acetabular rim also has forward flexion. That is, the rim is angled at 15 to 20 degrees off of the Anterior/Posterior plane, with the posterior portion farthest out, and the anterior portion farthest in. The combination of lateral opening and forward flexion help to prevent posterior and superior subluxation (dislocation) of the femoral head from the acetabulum.

The superior and posterior walls of the acetabulum are heavy, but the inferior wall is incomplete due to a notch in the bone. The acetabular notch blends into the acetabular fossa at the point where the ligamentum teres attaches.

The acetabulum is part of a synovial joint. Synovial joints are enclosed within a soft tissue structure - the capsule. The capsule is made up of dense fibrous cartilage and ligaments that connect the bones of the joint to provide

secure approximation while allowing movement. The capsule is lined by a synovial membrane. This thin, soft, smooth type of vascular connective tissue secretes synovial fluid and provides nourishment, as well as cushioning and lubricating the joint to minimize friction.

A rim of fibrocartilaginous tissue, the labrum, surrounds the acetabular margin. Because the labrum increases the depth of the acetabulum, the head of the femur sits very deeply in the socket. In fact, more than a hemisphere is received by the combination of the acetabulum and labrum. Therefore, the femoral head cannot be removed from its socket without stretching or tearing the labrum.

At the acetabular notch, the labrum is classified as a ligament (the transverse acetabular ligament). Skeletal ligaments are bands of connective tissue that link bones. They are composed of densely packed collagen fibers and are relatively inelastic. At joints, their main function is to provide stability and support while allowing motion. Ligaments which cross synovial joints blend into the wall of the capsule. In addition to the transverse acetabular ligament, which protects the edges of the bone and holds the femoral head in place, there are four other important ligaments in the hip joint capsule.

- 1) The iliofemoral ligament is the strongest in the body. This Y-shaped bundle of fibers extends from the ilium to the intertrochanteric line. It strengthens the anterior of the

joint so that the femur cannot be overextended.

2) The pubofemoral ligament runs from the crest of the pubic bone to the capsule and the lower part of the femoral neck. It serves an anterior strengthening function.

3) A broad, triangular ligamentous band on the posterior of the joint, the ischiofemoral ligament, arises from the ischium, below and behind the acetabulum. It covers most of the posterior aspect of the joint and strengthens the posterior capsule.

4) The ligamentum teres is a curved band that extends from the acetabular fossa to the head of the femur. Unlike the other ligaments described, its function primarily to supply blood to the femoral head and is not significant in strengthening the joint.

Cartilage is also found in the hip joint. Within the acetabulum, cartilage is thickest at the rim of the socket, the acetabular labrum, and thinner in the medial socket. A type of compact connective tissue, interarticular cartilage is comprised of dense groups of cartilage cells interposed between certain articulating surfaces such as the hip. Cartilage is able to withstand high pressure and tension, and is resistant to stretching; its function is to provide stability and cushioning. It lacks a nerve supply and contains no blood vessels. The perichondrium, a vascular layer, surrounds and supplies blood to fibrocartilage; it is also involved in the repair of injured cartilage.

CHAPTER 3

EVOLUTION OF ACETABULAR COMPONENT DESIGN IN TOTAL HIP ARTHROPLASTY

Total hip arthroplasty, the replacement of the ball and socket of the hip joint, is one of the most revolutionary advances in orthopaedic surgery. Early efforts to surgically correct deformities and increase motion in severely diseased hips involved total resection of the proximal femur (White, 1822) or osteotomy leading to pseudoarthrosis (Barton, 1827). Improved methods were sought as surgeons attempted to relieve pain and maintain stability of the joint.

Interpositional arthroplasty was then envisaged as a procedure to restore motion to a fused joint. The joint was divided and articulating surfaces were reshaped to original contours. Material was inserted to prevent refusion. Probably the first material used was wood; this actually preceded the x-ray, which was introduced in 1896.

The early 1900's saw increased interest in the use of implant materials, both inorganic and natural. Typically, though, surgeons relied on the body's own tissues for the interpositional membrane. Although arthroplasty was a curiosity, it was still seldom used in the treatment of deficient hips.

In 1923, Marius Smith-Petersen of Boston elevated arthroplasty to an effective procedure for severe hip disease with the advent of his "mould arthroplasty". He was looking

Facing 7

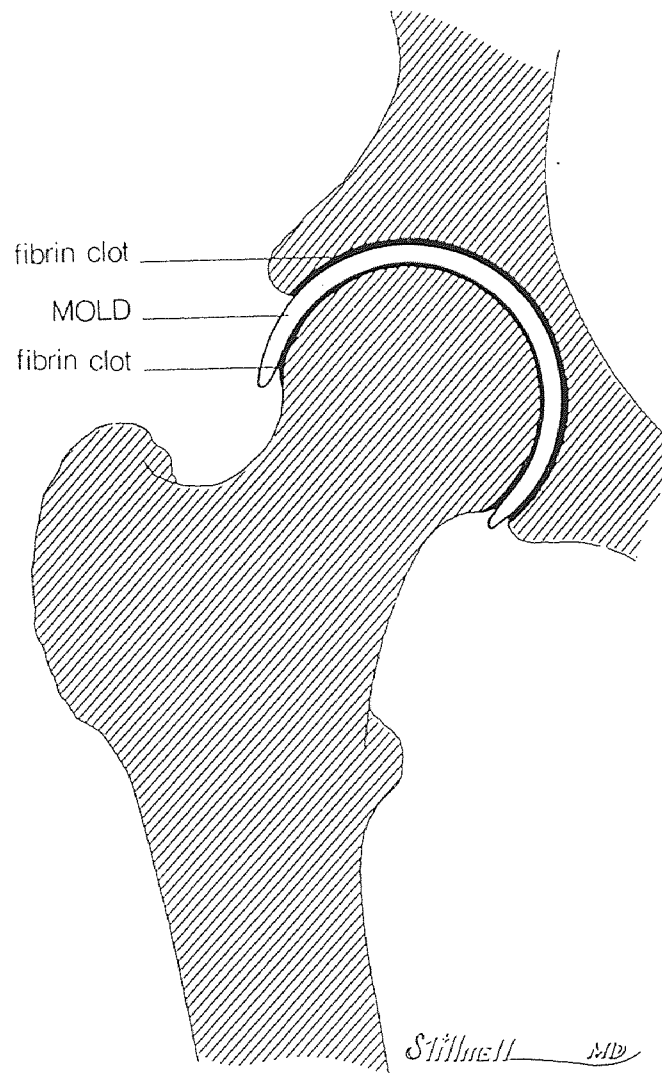


Figure 3 Mold Arthroplasty [49]

for a better interpositional material when he noticed a shroud of glass embedded in a patient. The glass was "lined by a glistening synovial sac, containing a few drops of clear yellow fluid." Smith-Petersen saw the resemblance to the synovial membrane surrounding a joint.

The goal of mould arthroplasty was to promote reformation of congruous cartilaginous surfaces. Smooth contours were created with reamers and gouges. Bleeding bone was exposed on both sides of the joint and a glass cup was inserted between the two surfaces. Ideally, the cup would mold fibrin clot into congruous surfaces which undergo metaplasia into fibrocartilage.

A landmark event occurred in 1939: Vitallium was introduced by Venable, Stuck, and Beach. This Co-Cr-Mo alloy offered durability with smoothness and passivity. The discovery of this first "ideal" orthopaedic alloy had a profound effect on the development of new designs in joint arthroplasty.

The first Smith-Petersen Vitallium cup was bell-shaped with a flared brim to maintain the position of the implant in the joint. In certain cases, the rim would get trapped in adhesions and become fixed in the socket. Subsequently, motion was only between the femoral head and cup. This inspired Smith-Petersen's assistant, Otto Aufranc, to remove the rim and match the inner and outer curves in his "true arc" Vitallium mold design. Aufranc's design allowed smooth motion



Figure 4 Aufranc's true arc Vitallium mold arthroplasty [49]




Figure 5 Hip-socket arthroplasty [49]

at the inner and outer surfaces without impingement.

Mold arthroplasty was based on sound principles and seemed reasonable physiologically. However, it was a technically demanding surgical procedure with unpredictable results. Nevertheless, it established a standard against which all later efforts were measured, until total hip arthroplasty.

Variations on mold arthroplasty led to several designs with deliberate fixation of the cup in the socket, with motion between a reshaped femoral head and polished cup: hip-socket arthroplasty. Some of these designs incorporated various fins and screw holes to secure the cup and resist rotation in the acetabulum. Most surgeons favored metal cups, but Harmon reported use of a plastic material: polymethylmethacrylate.

Other alterations of the mold concept took another approach. Aufranc's true-arc mold moved primarily at the cup-acetabulum interface, with little motion occurring between the femoral head and cup. This led to the femoral head prosthesis, which evolved into the fixed head endoprosthesis. It is still used in hemiarthroplasty procedures today.

Endoprostheses often resulted in failures on the acetabular side of the joint. The fixed head would wear through the acetabulum. This led to the addition of an acetabular component which significantly improved the treatment of arthritis on both sides of the joint. Metal-to-metal matched arthroplasties were thought to have low wear

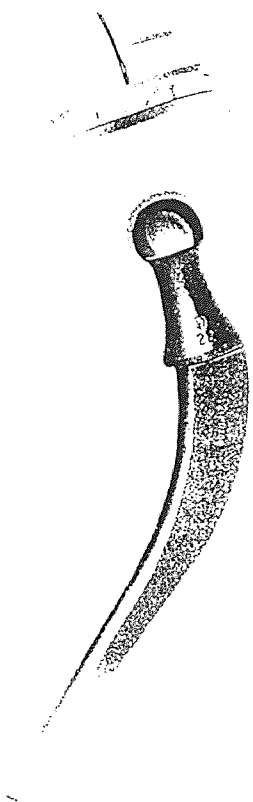


Figure 6 The Charnley low-friction arthroplasty [49]

properties, durability, and low friction torque. Also, the introduction of polymethylmethacrylate, bone cement, in 1950 greatly decreased problems of implant loosening.

The final major breakthrough to modern total hip arthroplasty is attributed to Sir John Charnley. His principles of low friction arthroplasty are still followed. Charnley noted that Femoral head prostheses would "squeak" due to the frictional resistance between the implant's head and the diseased natural acetabulum. He experimented with the use of teflon in the joint, then designed a femoral component which articulated with a thick-walled socket. Both components were fixed to the bone with bone cement. The small head used with a thick socket facilitated movement of the head, decreased shear forces, and favored cup fixation. Teflon was eventually abandoned in favor of ultra high molecular weight polyethylene (UHMWPE) for improved biocompatibility and wear characteristics. Charnley's prototype of the total hip arthroplasty, a cemented intramedullary stem, articulated with a low friction UHMWPE socket, is still the basic principle which modern designs are based on. Charnley was truly an inspiration to the art of total hip arthroplasty [49].

CHAPTER 4

SURGICAL TECHNIQUE

An extremely important part of total hip replacement is good preoperative planning. It will clarify the surgical steps, accelerate the surgical procedure, and assist decision making in the operating room.

4.1 Common Preparation

Identification of the appropriate acetabular implant size is easily accomplished by templating. The acetabular templates are placed on the A/P radiograph until the outer dimension of the component contacts good bone stock laterally, medially, and inferiorly. The smallest acetabular component that provides for adequate bone coverage should be used to preserve bone stock. This will be the size of the component used in surgery, or very close to it.

The surgical procedure begins with positioning of the patient on the operating room table in the lateral decubitus (laying on their side) position. The pelvis is leveled, anterior superior iliac spines paralleled, then the position is secured.

Drapes are applied to cover the perineum. The skin is prepped with alcohol, iodine, or other solution from the toes to above the superior margin of the ilium. Draping is continued to further ensure a sterile barrier. The final adhesive drape is placed over the wound, around the leg, and onto the superficial surgical drapes.

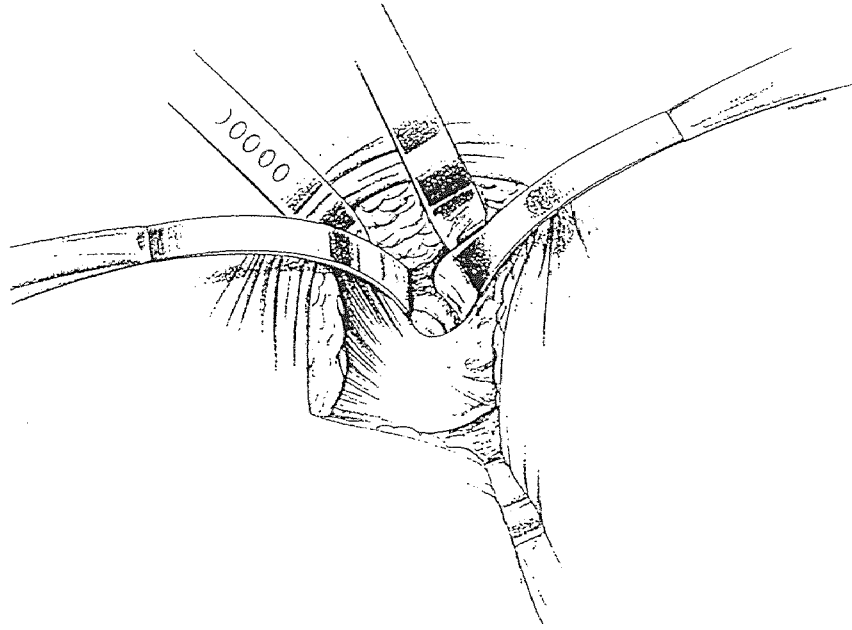


Figure 7 Capsulotomy [29]

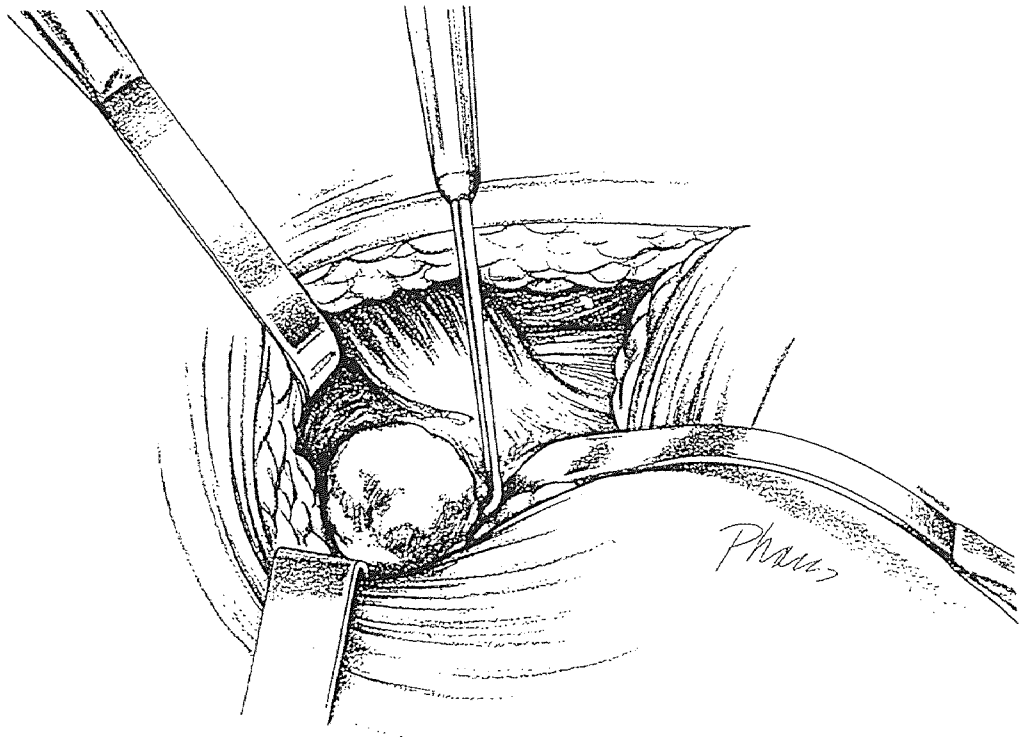


Figure 8 Dislocation of Hip [29]

The skin incision is made directly lateral in the axis of the femur, extending approximately 4 inches proximal to the tip of the greater trochanter and 5 inches distal. The length of the incision will vary depending on the thickness of the subcutaneous fat layer, the mobility of the joint, and the size of the patient. If bone grafting of acetabular defects is necessary, the proximal incision may be lengthened for adequate exposure. An initial skin retractor is then positioned and the fascia lata and the fibers of the gluteus maximus are split parallel to the skin incision. The short external rotators are identified and transected, exposing the femoral neck.

As the intertrochanteric ridge is crossed, the anterior capsule is encountered. A large window into the hip joint is made with an anterior capsulotomy. Further capsulotomy is performed superiorly and inferiorly to allow for freer dislocation of the femoral head.

The hip is flexed, adducted, and rotated out of the acetabulum. Some remaining fibers of the ligamentum teres may have to be cut to fully dislocate the hip.

A neck cutting guide is used to mark the osteotomy level on the femoral neck. An oscillating saw is employed to resect the neck. The femoral head may be retained as a source of bone graft. Preparation of the acetabulum may now commence.

The acetabulum is denuded of articular cartilage, fat pad, and remaining ligamentum teres. An acetabular reamer is

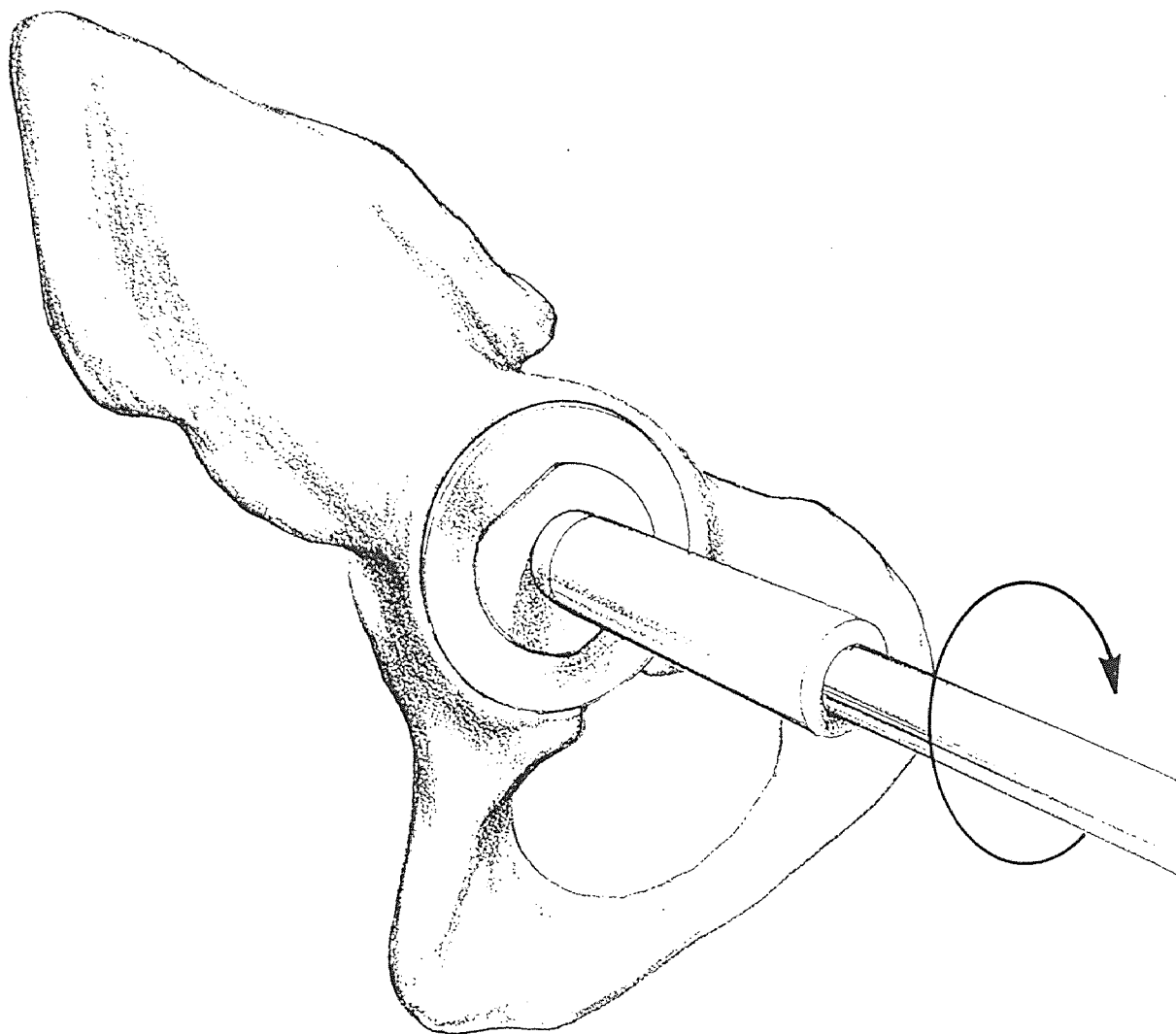


Figure 9 Reaming of the acetabulum [29]

now connected to the power source. The reamer should be debris-retaining to collect bone for grafting, if necessary.

Four of the most common acetabular conditions encountered in total hip arthroplasty are: anatomic positioning, superolateral subluxation, protrusio, and superior migration. Each will require a slightly different reaming technique to achieve proper implant positioning.

1) ANATOMIC POSITIONING: The normal axis of the acetabulum is approximately 35 degrees of lateral opening and 20 degrees of anteversion, or forward flexion. All reaming should take place along this axis. Begin with a small reamer which will deepen the socket to bleeding bone, while maintaining subchondral plate. Continue with a reamer one to two sizes smaller than the preoperatively templated size; this will circumferentially expand the acetabulum.

2) SUPEROLATERAL SUBLUXATION: When the medial wall of the acetabulum is substantially thickened by hypertrophy and osteophytes, the acetabulum will have to be medialized. The initial reaming will be transverse in order to avoid proximal displacement. After sufficient medialization has been achieved, expand the acetabulum in normal fashion.

3) PROTRUSIO: Mild to moderate protrusio requires medial reaming to expose bleeding bone. No deepening is required. Expansion is carefully performed to avoid further medialization by maintaining the reamer at the lateral opening. Severe protrusio generally requires medial bone

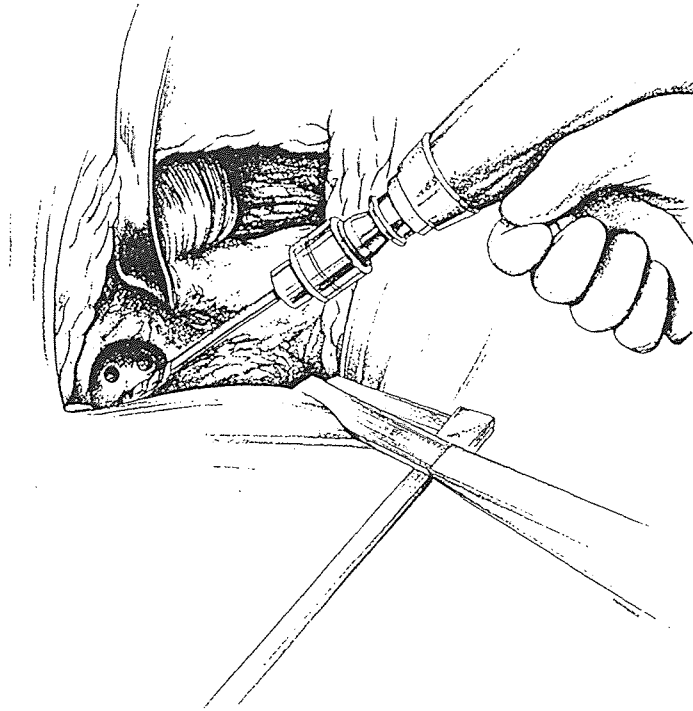


Figure 10 Drilling of cement anchoring holes [29]

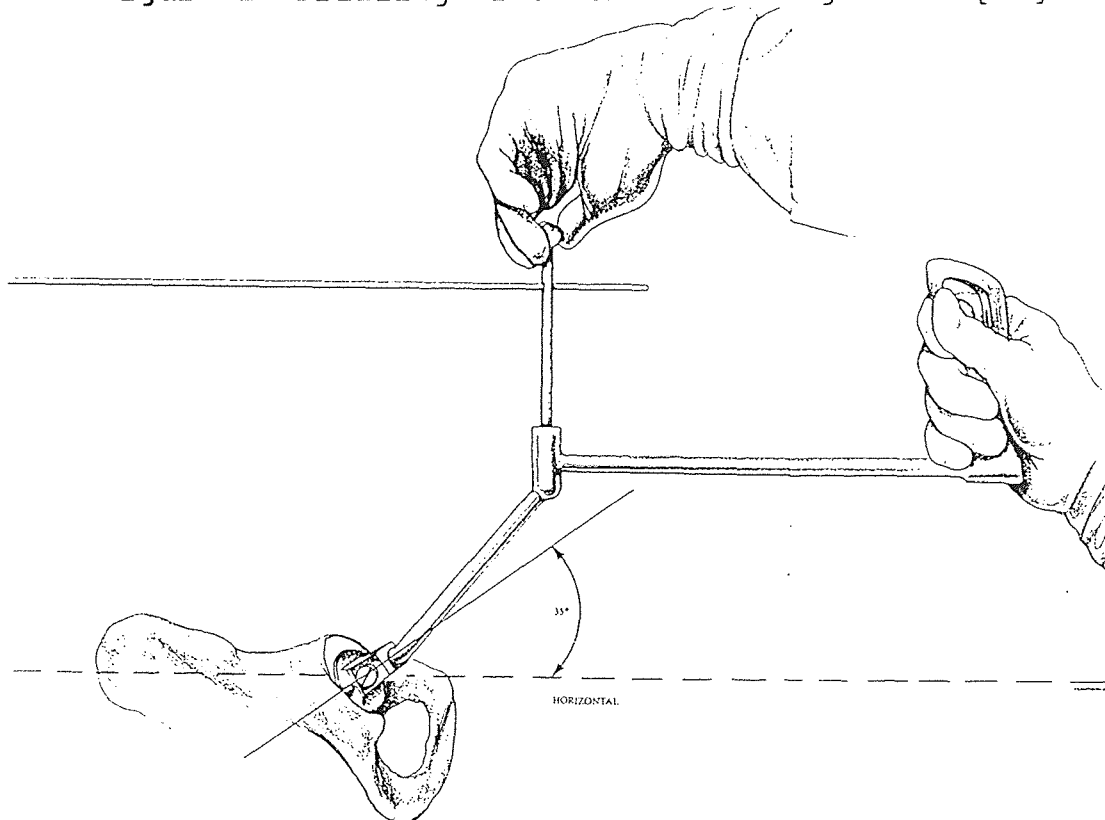


Figure 11 Implantation of cemented prosthesis [29]

grafting.

The medial bed for the graft is prepared by reaming with the size which fits the defect without expansion. The graft is fitted into the site. Further reaming to expand the acetabulum is carried out maintaining the reamer at the level of the lateral opening.

4) SUPERIOR MIGRATION: It is important to seat the component at the level of the normal acetabulum. This usually leaves a superior defect which requires bone grafting. For a severe defect the bed is prepared as above. The graft should be secured with rigid internal fixation, then preparation may continue in the normal fashion [24, 29].

Based upon the type of component being implanted, the final reamer size may vary. The surgical technique will be somewhat different for cemented versus cementless prostheses.

4.2 Cemented Implant

In the above reaming steps, cement may be substituted for bone graft to fill voids. Reaming is continued to the templated size. If necessary, continue until adequate bone stock is encountered.

Use an acetabular trial to check for proper sizing of the acetabulum. Be sure the trial is flush with the medial wall while filling the socket. Confirm the size of the trial which fits; this is the size of the final implant to be used.

Drill several anchoring holes in the ilium, ischium, and pubis. Lavage the acetabulum, suction, and dry the socket.

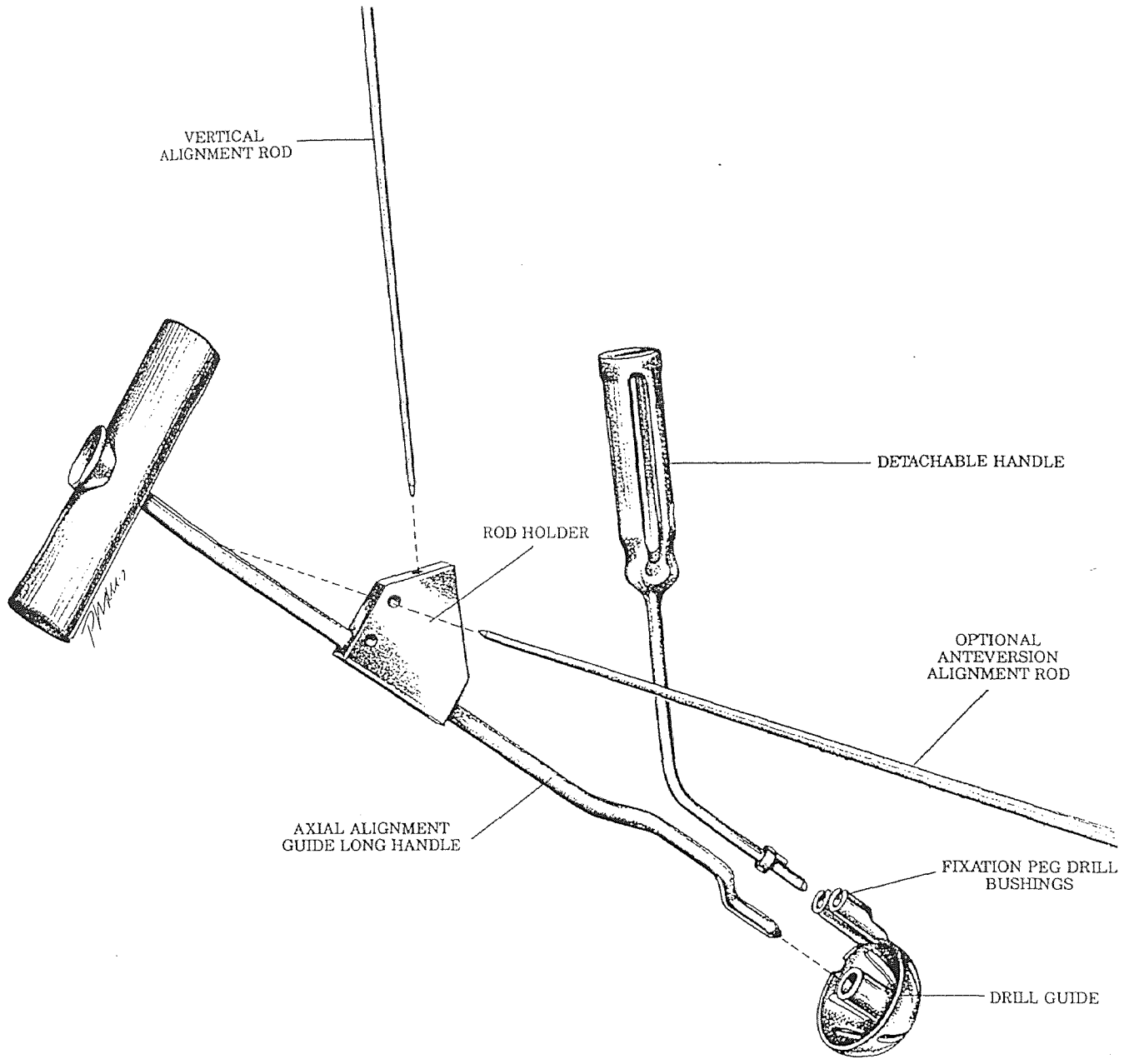


Figure 12 Drill guide instrumentation [24]

The cement may be manually introduced in bolus form, or injected with a cement gun. Pressurize the cement so it flows into the anchoring holes and covers the floor of the acetabulum.

Attach the implant to the cup positioning device. Most instruments will orient the component in the proper degree of abduction and anteversion. Insert the cup allowing the cement to pressurize and exude around the circumference. Wipe away any excess cement. Hold the positioner steady until the cement has cured. Finally, check for and remove any polymerized cement debris [29].

4.3 Cementless Implants

For press-fit components and porous ingrowth implants the acetabulum is reamed to anywhere from 1 to 3 mm smaller in diameter than the cup size being implanted. This amount of undersizing ensures that initial stability of the component will be achieved at the time of surgery.

A trial cup is inserted into the prepared acetabulum to confirm sizing and identify proper component positioning. The hood location to best prevent dislocation is determined. Reduction of the joint with trial components to check range of motion, stability, and leg length is performed and alterations are made as necessary. When all parameters are acceptable the actual implants can be introduced.

If the cup has pegs, fins, or spikes integral with its outer shell, holes may be predrilled to accommodate them.

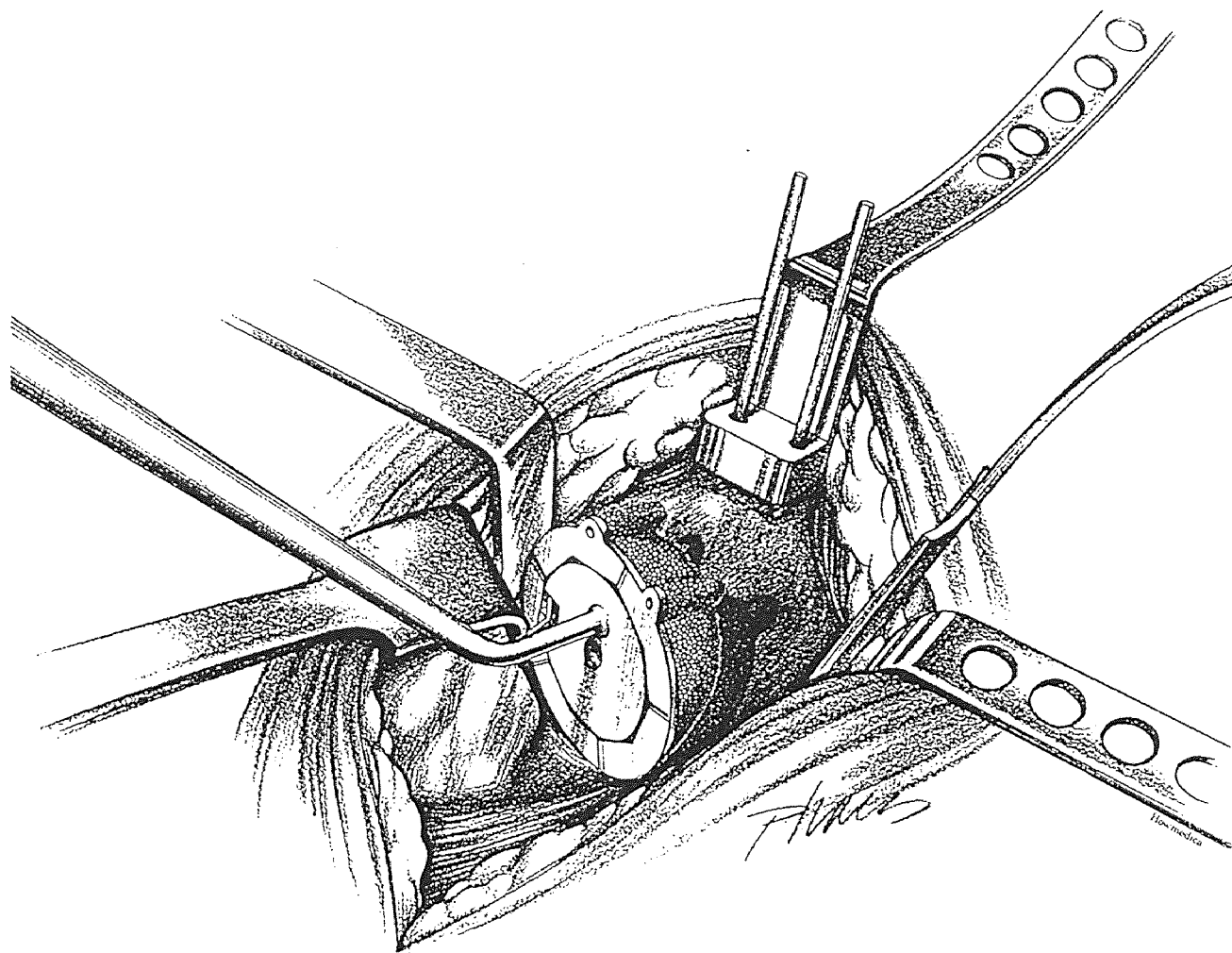


Figure 13 Implantation of cementless prosthesis [24]

Most systems will have a drill guide to accurately locate the holes. Finally, the acetabular implant is assembled onto its inserter and impacted into the acetabulum in the proper orientation. In the case of a two-piece cup, first the shell is implanted, then the liner is impacted into the shell.

Once the total joint is implanted and reduced, the wound is closed. Physical therapy begins one day post-op and patients are urged to bear weight on the hip within days of surgery [24].

Table 1 Torsional strength of anchoring hole patterns [38]

| Specimen type | Cross-sectional area of holes | Average rotation for max. torque | Average energy absorbed (N-m-deg) | Average maximum torque (N-m) |
|---------------|-------------------------------|----------------------------------|-----------------------------------|------------------------------|
| 1 | 3.40 | 17 | 1056 | 121 |
| 2 | 1.70 | 19 | 816 | 84 |
| 3 | 3.40 | 23 | 1789 | 157 |
| 4 | 3.40 | 15 | 1311 | 157 |

CHAPTER 5

ACETABULAR IMPLANTS

5.1 Cemented All Polyethylene

One of the simplest constructs of acetabular implant is an all polyethylene cup. The prosthesis is one-piece, with an inner diameter bored for articulation with a femoral head prosthesis, and the outer diameter fitted to the size of the host acetabulum.

5.1.1 Longevity of Fixation

There are many factors involved in the longevity of cemented acetabular component fixation. Indong Oh [38] performed a comprehensive analysis of four such factors: bony bed preparation, pressurization of PMMA, shape and thickness of the cement mantle, and design features of the polyethylene cup.

To provide firm cement fixation of a cup, several anchoring holes are typically drilled into the acetabulum before the cement and implant are introduced. This serves to increase the torsional resistance of the bone-cement interface. Oh tested four different hole patterns for the maximum torque to failure, as described in table 1.

The simulated sockets with six, 0.85 cm diameter anchoring holes, 0.8 cm deep gave the highest resistance to torsional forces. The added step of rounding the edges of the holes to alleviate stress risers did not show any exceptional affect and, therefore, is probably not worth the effort. Oh

| | | | |
|---------------------|---------------------|---------------------|---------------------|
| | | | |
| | | | |
| 3 | 3 | 6 | 6 |
| 8 mm ID | 12 mm ID | 8 mm ID | 8 mm ID |
| STRAIGHT EDGE | STRAIGHT EDGE | STRAIGHT EDGE | ROUNDED EDGE |
| 1.7 cm ² | 3.4 cm ² | 3.4 cm ² | 3.4 cm ² |

Figure 14 Cement anchoring hole patterns [38]

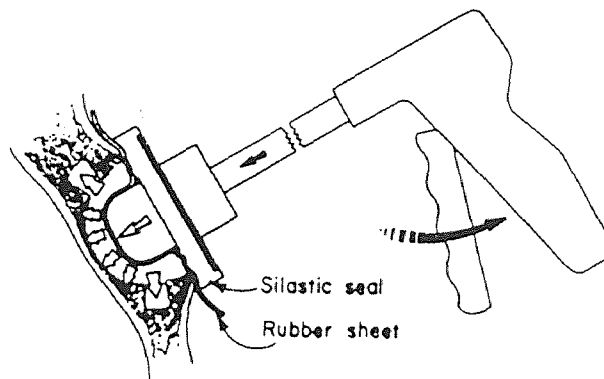


Figure 15 Cement pressurizing device [38]

recommends using multiple small anchoring holes to help reduce the potential of long-term loosening because more fracture surfaces need to be created for failure than with fewer large holes of the same total cross-sectional area. Shallow holes are effective, easy to make, and have a far less chance of penetrating through the acetabulum.

Other determining factors in improving fixation of the acetabular cement include the duration of sustained pressure on the injected cement, the depth of intrusion of the PMMA, and the final cement quality. Hand-packing was compared to compaction with a pressurizing device at two stages of polymerization of the cement. The degree of intrusion of the cement into the bone depended on the pressure applied to it. The compactor gave higher intrusion depth values; it forces pressure to build in the cement mass because there can be no escape of cement outside of the acetabulum. Obviously, using cement in the earlier stages of polymerization when it is less viscous will also result in a higher intrusion depth. However, at this stage, cement cannot be packed by hand.

Maintenance of high pressure also has a positive effect on the resulting cement mantle. Instantaneous high pressure, as seen in finger packing, does not cause uniform intrusion over the large area of the acetabulum.

The shape and thickness of the cement mantle surrounding an implant is also a factor in arthroplasty. By bonding strain gauges into the cement layer 1 mm from the cup surface,




Figure 16 All-polyethylene acetabular implant [49]

Oh was able to measure cement strains for various cup placements. He found that inserting a cup too deeply, inferiorly, or superiorly into the acetabulum resulted in higher tensile strains in the cement than when the cup was placed concentrically into the same size acetabulum. In addition, the uniform concentric mantle had more evenly distributed stresses than when the cup was eccentric in the socket.

Another trend Oh saw was that as the cement mantle increased in thickness, the magnitude of the strain in the cement decreased. However, there are other factors which limit the maximum thickness of cement: the size of the acetabulum, the outer diameter and thickness of the cup, and the effects of heat generation during PMMA polymerization. All factors considered, a 3 mm mantle has been widely accepted as the industry standard.

5.1.2 Design Features

Design features of a cemented all-polyethylene acetabular implant should include integrated spacers to ensure an even cement mantle of approximately 3mm. Also, grooves on the outer surface of the cup will increase the surface area interdigitating with cement for a superior cement-implant bond. Shallow grooves are adequate for fixation, plus they maintain a thicker polyethylene implant [29,49].

5.1.3 Finite Element Analyses

Two-dimensional finite element analyses of the acetabular

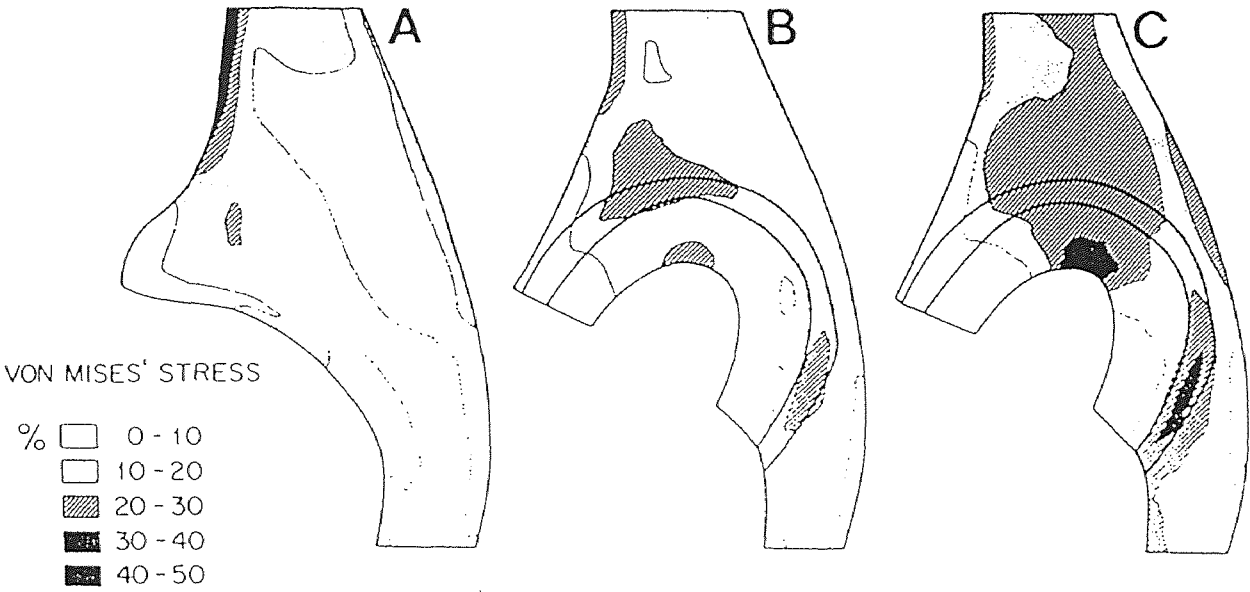


Figure 17 Von Mises' stresses for A) normal acetabulum, B) THA with diffuse pressure, C) THA with concentrated pressure [52]

region before and after hip replacement with a cemented polyethylene component were conducted by Vasu, Carter and Harris [52]. The distribution of pressure in the acetabular region for a single-legged stance was modelled as nodal loads to simulate *in vivo* loading conditions. A nonhomogeneous distribution of bone elastic properties was incorporated into the models. To investigate the levels of stress relative to the yield stress for the implant, PMMA, and bone, the von Mises' stresses were calculated and plotted (figure 20). However, these values are slightly misleading since the von Mises' criteria does not account for the greater strength of dense bone in compression than in tension.

The stresses calculated by this model are obviously too high, or else rigorous activity would cause rapid fracture of the acetabulum. A two-dimensional model such as this, which does not consider support from the rest of the pelvis, cannot be used to quantitatively estimate stresses in the acetabulum. Qualitatively, though, the results make sense. Compressive stresses were seen on the lateral wall and tensile stresses were seen on the medial wall, portraying a bending of the ilium due to contraction of the hip abductors. The stress patterns are also consistent with the orientation and density of trabecular bone in the acetabular region.

After joint replacement, there is a distinct change in stress transmission. Forces push the cup up into the cancellous bone between the medial and lateral walls of the

ilium, resulting in increased principal stresses superior to the cup. Tensile stresses are created in the cement layer. The direction of load transfer is now more toward the interior of the ilium. The lateral lip of the acetabulum experiences lower stresses than before THA, while the medial wall sees an increase in bone stresses. These high stresses may correlate to the common failure modes of loosening and medial migration of acetabular implants.

5.1.4 Effects of Bone Cement

Heat generation and conduction of polymethylmethacrylate during fixation of an all-polyethylene component in the acetabulum was analyzed by Huiskes [23]. The cup, cement, and bone were considered in his axisymmetric model, while heat loss to the surrounding tissues was described by a boundary condition.

The temperature reached during curing of the cement as a function of time was calculated for nodal points in the element mesh. In the middle of the cement mass, the temperature reached 110°C. The bone at the cement-bone interface saw 57°C, while the implant reached 69°C at the implant-cement interface. The temperatures in the bone were less than those in the cup due to the superior heat capacity and conductivity of the bone and the larger surface area of the bone-cement interface. Still, areas of the bone near anchoring holes were susceptible to tissue necrosis since they are somewhat surrounded by cement.

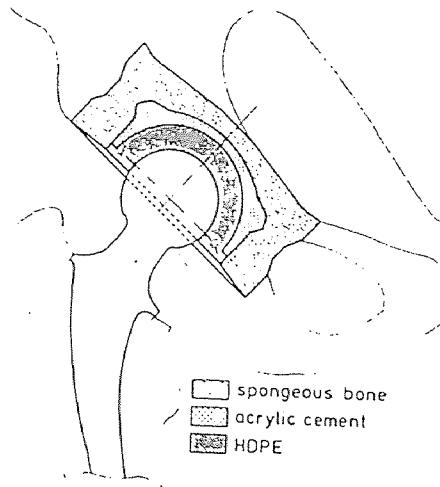


Figure 18 Schematic section of modelled acetabular cup fixation system [23]

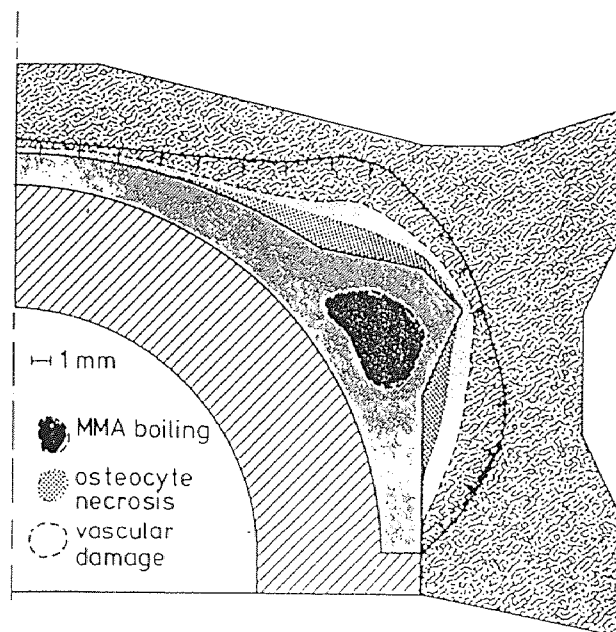


Figure 19 Huiskes' "necrosis map" [23]

Huiskes "necrosis map" is shown in figure 22; it should not be regarded too absolutely though, since several parameters values are somewhat uncertain. However, the basic results are clear: the possibility of thermal necrosis can be reduced by avoiding the application of large masses or thick layers of cement.

5.1.5 Clinical Results

High density polyethylene was first introduced as a material for acetabular components in 1962. Charnley and DeLee [7] reported their results using these cemented cups implanted from November 1962 to December 1965. Their prospective ten year study was undertaken to assess radiological demarcation of the socket.

Of the 141 Charnley low-friction arthroplasties performed, 69% showed demarcation of various degrees and 9.2% had progressive migration of the cup. Since nearly 30% showed no demarcation after 10 years, Charnley and DeLee believed that cementing the acetabular component was still viable, and that an improved surgical technique may reduce the occurrence of demarcation. They recommended three steps to help achieve a better bone-cement bond:

- 1) Obtain hemostasis before cement insertion. Cement will adhere better to a clean, dry wound.

- 2) Increase the pressure with which cement is applied to the acetabulum. Higher pressures will force cement into the interstices of the bone. "Coining" blows through the socket

or a water-filled rubber tampon applied to the cement before cup implantation are two methods of pressurization.

3) Remove the cup holder early after introducing the cup since surgeon movement could prevent the stability needed for the cup to set properly in the cement. Then employ an acetabular pusher to apply pressure during curing. [de]

Using these new techniques, Charnley *et al.* [17] began another study on patients operated on in 1967 and 1968. The purpose of this evaluation was to find radiological signs of pathology at the bone-cement interface which may indicate pending failure. Criteria for incipient failure included socket demarcation of 1-2 mm or cavitation of acetabular bone. Five hundred and forty-seven hips with an average follow-up of 8.3 years were reviewed. Mechanical failure of the cement-bone bond only occurred in 2.2% of the cases. Radiological evidence of failure in the absence of clinical symptoms was found in 12% of the cases - a vast improvement over the last study.

Charnley arthroplasties are some of the best for examining long-term results using a cemented polyethylene socket. In 1992, Wroblewski, Taylor and Siney [55] reviewed 57 such cases with a 19 to 25 year follow-up.50 Clinical results remain excellent with 75% pain free and 19% with occasional discomfort. However, clinical results do not reflect radiological appearance. Evidence of loosening appeared on 25% of the radiographs, though the sockets remain

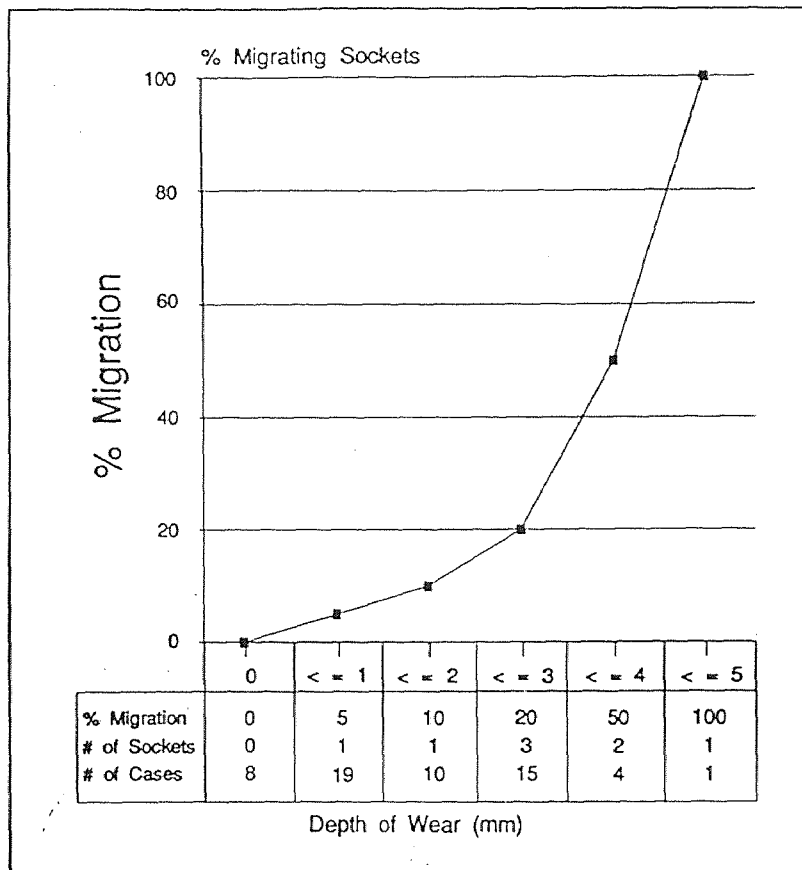


Figure 20 Correlation between the depth of socket wear and the incidence of socket migration [55]

clinically asymptomatic. A correlation between the depth of socket wear and the incidence of socket migration was discovered. There appears to be an exponential relationship as illustrated in the graph in figure 23.

The cause of loosening in cemented polyethylene cups is still under investigation today. Charnley was heading in the right direction with improved cementing techniques, as evidenced by his clinical results. There are other factors affecting the longevity of these implants, too. The underlying disease in the joint has been indicted. Patients diagnosed with rheumatoid arthritis or avascular necrosis had higher incidences of cement-bone radiolucency than patients with osteoarthritis [46]. Also, studies have stated that younger patients have a significantly higher rate of loosening than older patients [46]. Another possibility, proposed by Sarmiento *et al.* [45], is cup containment. Implants completely contained by acetabular bone had a lower incidence of continuous radiolucency than partially contained cups. Vertical orientation of the cup to obtain full coverage was preferable to neutral positioning with partial containment. The hypothesis is that when the load across the hip joint is directed upward and lateral, a horizontal cup is susceptible to tilting. This sets up high tensile stresses in the medial socket which disrupt the bone-cement bond and eventually lead to loosening.

With proper patient selection, an all-polyethylene cup is

still a viable option for reconstruction of the acetabulum. The ever increasing pressures of cost containment in the medical industry make this implant an even more attractive choice, as it's price is approximately one-half that of a cementless two-piece cup.




Figure 21 Cemented metal-backed prosthesis [29]

5.2 Cemented Metal Backed

5.2.1 Finite Element Analyses

The addition of metal backing to the all-polyethylene acetabular component, originally designed by Harris in 1971 to permit replacement of a significantly worn polyethylene liner, has been universally accepted as a means of reducing peak stresses at the bone and cement interfaces. Finite element analyses by Carter, Crowninshield, and others [2,5,52] gave an engineering basis to clinical beliefs.

Carter, Vasu, and Harris [2] continued their study of stress distribution in the acetabular region, as first discussed in the previous chapter. This time the effects of cement thickness and a 2mm cobalt-chromium backing were incorporated into their finite element analyses. The features of each of the models they tested are presented in table 2.

Table 2 Finite element models tested by Carter, *et al.*

| <u>Model</u> | <u>Cement thickness</u> | <u>Metal backing</u> | <u>Load distribution</u> |
|--------------|-------------------------|----------------------|--------------------------|
| 1 | 3 mm | none | diffuse |
| 2 | 1 mm | none | diffuse |
| 3 | 5 mm | none | diffuse |
| 4 | 3 mm | 2 mm | diffuse |
| 5 | 3 mm | 2 mm | concentrated |

The stress distributions calculated for models 1, 2, and 3 which incorporated cement layers of 1, 3, and 5 mm,

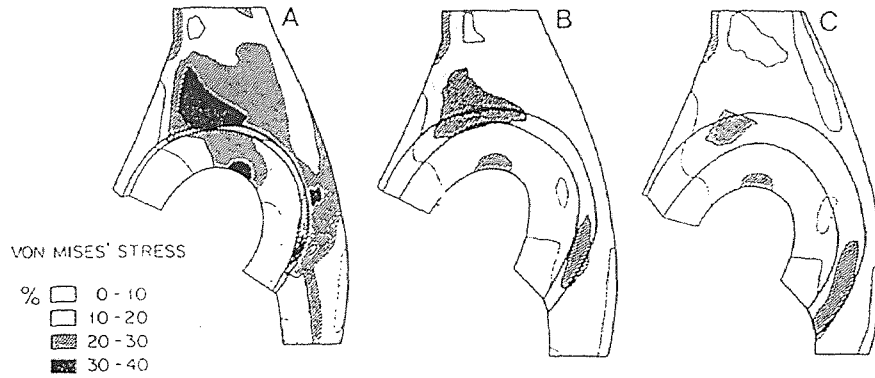


Figure 22 Von Mises' contour plots as a percentage of yield stress for non-metal-backed components for THA, A) 1mm PMMA, B) 3mm PMMA, C) 5mm PMMA [2]

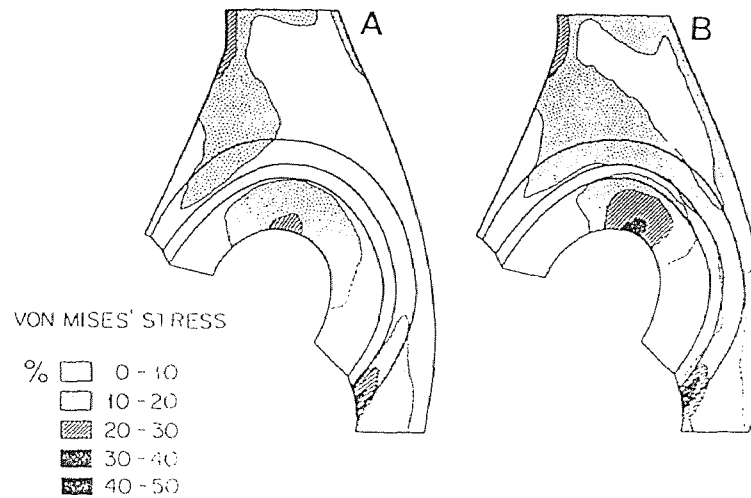


Figure 23 Von Mises' contour plots as a percentage of yield stress for metal-backed components for THA, A) diffuse pressure, b) concentrated pressure [2]

respectively, were qualitatively similar. However, a distinct trend in the magnitudes of the stresses emerged - increasing cement thickness tended to decrease the stress magnitudes in the cancellous bone, the medial wall of the ilium, the cement, and the cup.

The addition of metal backing also caused a marked change in stress distribution. The stresses were redistributed throughout; they were reduced in the cancellous bone, the medial wall of the ilium, the cement, and the cup. The metal shell transmitted the high bending and tensile stresses to more peripheral areas.

When a concentrated load was applied through the cup, slightly higher stresses were seen in the four areas mentioned above, than with a diffuse load. The metal backed cup with a concentrated load was still an improvement over an all polyethylene cup with a diffuse load and 5mm cement mantle.

Overall, Carter *et al.* identified four areas at risk from their finite element study: 1) the cancellous bone immediately superior to the cup, 2) the cement, 3) the medial wall of the ilium, 4) the prosthesis. Failures in areas 1 and 2 are likely contributors to migration and socket loosening. Failure in area 3 could lead to a protrusio condition.

The authors concluded that increasing the stiffness at the back of the component prevents penetration of the cup through the ilium by distributing stresses over a wider area. Bone at the periphery bears a greater portion of the load than

with a more flexible cup. However, one area of concern arises. Stresses are high inferiorly in the cement layer with increased cup stiffness. This may just be an artifact caused by two-dimensional modelling. All in all, though, this analysis agrees with the conclusions drawn by VanSyckle and Walker [51] in their numerical model.

An axisymmetric finite element model with non-axisymmetric loading of an acetabular prosthesis was presented by Pederson *et al.* [40]. Two acetabular component design parameters were considered in this study. The first was variation in prosthesis wall thickness achieved by adjusting the femoral head cavity while maintaining a constant outer diameter. The second was metal backing of the acetabular component.

Implant wall thicknesses of 3.5 to 14.5 mm were evaluated. With thinner walled components, stress levels increased substantially within the PMMA. The addition of metal backing abridged the effect of wall thickness and held cement stresses at a constant and relatively low level.

This study also indicates that the acetabulum's relatively stiff subchondral shell experiences large tensile stresses during hip loading. Those stresses are increased when load transmission occurs through flexible acetabular components. Metal backing stiffens the prosthesis and greatly reduces maximum subchondral bone stresses.

Subchondral bone may erode due to arthritis, or may be

removed by the surgeon (i.e., excessive reaming, drill holes). Pederson's study shows that stress levels within the PMMA and trabecular bone are increased when subchondral bone is removed. If acetabular prosthesis loosening is in part related to cement and bone overloading, then thicker walled, metal backed components implanted with preservation of the subchondral plate are recommended to reduce the incidence of failure.

5.2.2 Design Features

Certain design features on cemented metal backed cups can prolong their fixation. Textured or grooved surfaces will enhance the cement-metal bond. Also, integral PMMA spacers ensure an adequate cement mantle of uniform thickness for optimum stress distribution. Finally, lower profile implants will allow complete bony coverage, while maintaining the strong subchondral plate [29,49].

5.2.3 Clinical Results

Clinical data which support the analytical evaluations have been reported. Harris and White [21] carried out a follow-up study of fifty-three hips performed with a metal backed component. To assess whether or not metal backing was effective in prolonging the duration of fixation, they compared their results to those of Dorr and Takei [8] for polyethylene sockets. The parameters and results of each study are given in table 3:

Table 3 Parameters of Harris and Dorr studies [21]

| | <u>Non-metal Backed</u> | <u>Metal Backed</u> |
|----------------------|-------------------------|---------------------|
| No. of hips | 43 | 34 |
| Follow-up (years) | | |
| Shortest | 5 | 5 |
| Average | 6.5 | 6.5 |
| Longest | 9 | 8.7 |
| Patient Age (years) | 45 maximum | 45 maximum |
| Status of prosthesis | | |
| Loose, revised | 5 | 2 |
| Loose, not revised | 1 | 1 |
| Impending failure | 7 | 0 |
| Total | 13 (30%) | 3 (9%) |

Three critical factors in evaluating looseness are: 1) age of the patient, 2) duration of follow-up, and 3) criteria for looseness. All factors were similar for the two studies. Looseness was defined as motion of the component at operation or migration on plain radiographs. Impending failure was defined as severe disruption of fixation characterized by a continuous radiolucent line at least 2 mm thick along the cement-bone interface.

Comparison of the results showed a marked reduction of statistical significance in both impending failure and looseness with the metal backed acetabular component. In view of these clinical data and the finite element analyses, Harris

and White recommended the use of metal backed prostheses for total hip replacement.

Further follow-up to this study was performed by Harris and Penenberg [20]. At a minimum of ten years, 41 per cent of the cups were loose or impending failure, primarily in patients less than thirty years old.

With controversial clinical results reported on the use of metal backing, Ritter *et al.* [44] evaluated a series of 203 patients who had 238 primary cemented total hip replacements. The femoral component, cement technique, surgeon, criteria for operation, and postoperative care were the same for all patients. One group received metal backed prostheses, the other received all polyethylene cups. Statistical comparisons between groups were made with Kaplan-Meier survival analysis. Three definitions of failure were used: a complete radiolucent line greater than 1mm in width surrounding the component, prosthetic migration of more than 5mm, and revision of the component.

Charnley hip scores for function, pain, range of motion, and walking did not differ significantly between the two groups. The weight of the patient and the size of the cup implanted were determined to have had no effect on the rate of failure. However, according to all three definitions of failure, metal backed acetabular components failed significantly sooner. The rate of radiolucency was 39%, migration was 4%, and revision was 6% for the metal backed

parts compared to 23%, 2%, and 2% respectively for the all-polyethylene cups.

This consecutive, well matched, retrospective analysis cast doubt upon the use of metal backed cups. Therefore, Ritter [43] reviewed the data using regression analysis. Neither patient sex, diagnosis, weight, nor cement thickness had an effect on loosening. Age less than 60 seemed to be a factor, and once again, metal backing. Also, upon examination of the rate of wear, Ritter found that the all-polyethylene cup wore at .08mm per year versus .11mm per year for the metal backed cup. If wear debris relates to loosening, this helps explain the poorer results seen with the metal backed prosthesis.

The controversy between cemented metal backed and all polyethylene components continues. Though many surgeons jumped on the bandwagon of the "new technology" of metal backing at the time, the trend may revert back to the Charnley days of thick polyethylene cups. Cement techniques have improved over the years, as well, which will contribute positively to clinical results using all-polyethylene implants.




Figure 24 Cementless acetabular implants [24]

5.3 Cementless Components

5.3.1 Design Rationale

Long-term loosening associated with the use of PMMA fixation of prostheses compelled efforts to develop a more durable mechanism of biologic fixation. *In vivo* data have demonstrated that bone grows into surface pores in inert materials in both loaded and unloaded implants, provided that the pore size is in the range of 150 to 400 μm . This bony ingrowth can lead to shear strengths at the implant/bone interface that exceed those of trabecular bone itself [13].

The accumulated experimental and clinical evidence [13,18] has defined three events which must occur in sequence for bone ingrowth fixation to occur:

1) Stable initial fixation

The initial stability of an uncemented component depends on several factors including the strength of the local bone, friction at the bone/implant interface, and the magnitude of stresses acting on the component. Until mechanical interlocking of new bone exists, motion will occur if any forces become greater than the local bone or frictional interface can withstand. Reaming the acetabulum to a smaller size than the implant is performed in an attempt to gain good initial stability. Some surgeons feel that additional means of fixation are necessary to provide the security required. One such method, placing screws through the component into the acetabulum, will be discussed in a later section.

2) Bone ingrowth

The process of bony ingrowth into porous surfaces is essentially fracture healing. After the component is implanted, blood fills the interface. Bone forms primarily by intramembranous ossification in areas of immobilization and by endochondral ossification in sites where micromotion is occurring. Two elements necessary for bone healing are cells capable of forming bone and a blood supply. It is not surprising that ingrowth is greatest at points where the porous surface is intimately applied to viable vascular bone.

3) Bone remodeling

Remodeling is a complex process referring to the continuous resorption and formation of bone. It allows the skeleton to adapt to loading conditions to which it is subjected. With increased loading comes increased cortical thickness. Remodeling requires a blood supply and bone cells, and is essential for maintenance of implant fixation.

5.3.2 Clinical results

Galante reported satisfactory initial results using a porous surfaced acetabular component [13]. Fixation was very adequate and the radiological appearances showed good interfaces. He did note, though, that the recovery of these patients is somewhat slower than with cemented components. Restrictions on activity must be imposed for some time to allow the bone ingrowth and remodeling process to take place.

At the 1987 meeting of the Orthopedic Research Society,

Sumner *et al.* [50] presented a series of retrieved human cementless acetabular prostheses. These components had been removed for reasons other than loosening, typically recurrent dislocation, and were collected from across the United States. In 17 of 19 specimens bone ingrowth was identified. The average overall amount of bone apposition was 7.5% and bone ingrowth was 19.9%.

Harris [18] performed 126 total hip arthroplasties using a cobalt-chrome porous coated acetabular implant with screw fixation through peripheral flanges in 52 cases, and a titanium fiber mesh coated socket with screws through the hemisphere in the remaining 74 hips. Emphasis was placed on radiographically analyzing acetabular component fixation by monitoring radiolucencies at the bone/implant interface and migration of the cup.

Overall, his results at an average follow-up of 42 months were excellent. The mean Harris hip score was 93 points, with no or slight pain in 94% of the patients. No acetabular component had to be revised, and review of radiographs showed that only one cobalt-chrome component migrated superiorly. In addition, Harris felt that the reduced operating time and decreased intraoperative blood loss were positive factors associated with cementless sockets.

In 1976, a high-density polyethylene acetabular component with integral pegs was developed by Freeman [14] for uncemented use, with the aim of achieving iso-elasticity

between the bone and implant. Twenty-one of these cups were implanted and reviewed post-operatively for pain, mobility, and radiological appearance. Early results were favorable and the unchanging radiographic appearance was encouraging.

At about the same time, a similar all polyethylene cementless cup was designed by Morscher [54]. Again, the initial clinical results were positive, and between 1977 and 1982 a total of 545 were implanted. However, a review at 5 to 10 years revealed otherwise.

A high rate of radiological loosening was seen after the sixth year, and a high rate of clinical loosening after the eighth year. Loosening was more common in women, younger patients, and where a small size component was used. Histological examination of 23 cups found that there was rarely bone integration into the surface grooves on the cup. In cases of obvious loosening, granuloma with polyethylene debris were found and wear was very marked. Whether the polyethylene debris caused wear and loosening, or the loose component generated wear debris, could not be determined. Regardless, Morscher abandoned use of this prosthesis, in favor of a modified design.

In an effort to maintain the elasticity of his acetabular implant, while offering a porous ingrowth surface, Morscher bonded surface layers of titanium mesh to the polyethylene cup [35]. To maximize the bone/implant surface area and promote initial stability, the mesh was roughened by blasting.

From 1985 to 1987, 387 of these cups were implanted in osteoarthritic patients. At a follow-up of 12 to 39 months over 85% showed perfect radiographic osseous integration without radiolucencies or migration. Only one cup was loose, and 2 cups migrated over 2mm. The histologic picture of a cup retrieved from a patient who died 33 days post-operatively showed extensive bony ingrowth into the mesh. These results suggested an optimistic prognosis for this cup. Morscher is still using this prosthesis.

The osseointegration of a smooth, titanium press-fit implant was analyzed by McCutchen, Collier, and Mayor [32]. Three primary modes of fixation were incorporated in the design: two titanium pegs protruded through the edge of the cup, screw holes, and circumferential grooves. Clinical findings were excellent at one year, and radiographs remained unchanged at two years, pointing to the attainment of immediate stability with this prosthesis. Of course longer follow-up will be required to determine the acceptability of this implant.

Collier [3] was also involved in an histological evaluation of three different types of retrieved porous coated acetabular cups. Objectives of the study were to determine the efficacy of porous coating for ingrowth, the role of porous coating characteristics, and identification of areas for ingrowth.

Only 16% of the components showed bone ingrowth. Pore

size did not seem to be a determining factor, and ingrowth into titanium was indistinguishable from that into cobalt-chrome. The prostheses retrieved for looseness generally showed a fibrous layer separating the implant from the bone, and were implanted, on average, for less than one year.

Although the results sound poor, it must be noted that all of these components had been retrieved for a variety of reasons, typically looseness. Also, variables such as surgical technique, patient selection, and implant selection were not controlled. The study does suggest that initial stability is a prerequisite for bony ingrowth.

Clinically, bone ingrowth fixation is successful when applied properly. Results showing acetabular fixation predominantly support the concept of porous ingrowth; many surgeons now prefer bone ingrowth prostheses for socket reconstruction.

5.3.3 Adjuvant fixation and screw placement

A biomechanical comparative study of *in vitro* initial stability was performed at the University of North Carolina [27]. Three-screw fixation, two-peg fixation, and three spike fixation porous acetabular cups were implanted in cadaveric samples. Measurements were taken to quantify the relative motion occurring at the prosthesis/bone interface under physiologic load, and to determine the fixation limit of each prosthesis.

None of the cups failed at 200 pounds of axial load;

deformation at that load was statistically equal for all three designs. Acetabular component motion with torque testing showed that the screw fixation prostheses were able to withstand significantly higher torque before failure than the two-peg or three-spike cups. The measured maximum torque of 46 N-m was much less than that obtained by Oh (157 N-m) for cemented polyethylene cups in hardwood blocks, but similar to other studies using cadaver pelvises. Fixation using three cancellous screws is recommended by the evaluators for two reasons: greater initial stability and an easier surgical technique since pre-drilled locational holes are not required.

A prerequisite for durable fixation of cementless acetabular components is elimination of motion between the cup and bone. Clinical experience shows that exceptional stability is achieved if the acetabulum is reamed to a hemisphere, a hemispheric prosthesis is implanted, and screws are added to anchor the cup to the acetabular bed. Biomechanical studies, such as the one discussed above, and analysis of retrieved implants support this clinical data.

Noble's [37] measurements of micro-motion of the acetabular prosthesis *in vitro* demonstrated that the use of screws substantially increased the stability of the cementless interface, especially under large torsional loads. This is consistent with the hypothesis that screws pull the somewhat elastic acetabulum and prosthesis together, thereby allowing load sharing across a larger contact area, and reducing the

likelihood of implant loosening or motion. Also, research has shown consistent ingrowth of bone in the vicinity of screws, even when the rest of the porous surface is sparsely covered.

When selecting bone screws to augment cup fixation, the length of each screw and its placement in the acetabulum must be considered. A small but serious number of neurovascular injuries and intraoperative deaths have occurred when screws penetrated the pelvis. This is often attributed to an attempt to obtain bicortical fixation for maximum thread purchase. Two potential measures for prevention of neurovascular injuries have been proposed. First, restrict screw placement to the posterior half of the acetabulum to avoid puncturing risky structures; namely, the external iliac artery and vein and the femoral nerve. Unfortunately, there are numerous other structures, including the superior gluteal artery and the obturator vessels, which may be compromised by penetration of the postero-medial wall.

The second thought is to rely upon unicortical fixation. Structures are protected since drills and screws never violate the intrapelvic space. However, for unicortical fixation to be effective, screws must be strategically placed within "safe" zones in the pelvis where bone of adequate strength and thickness is available.

Noble [37] conducted studies to guide in unicortical screw placement. First, he analyzed the topographical variations in periacetabular bone by sectioning pelvis

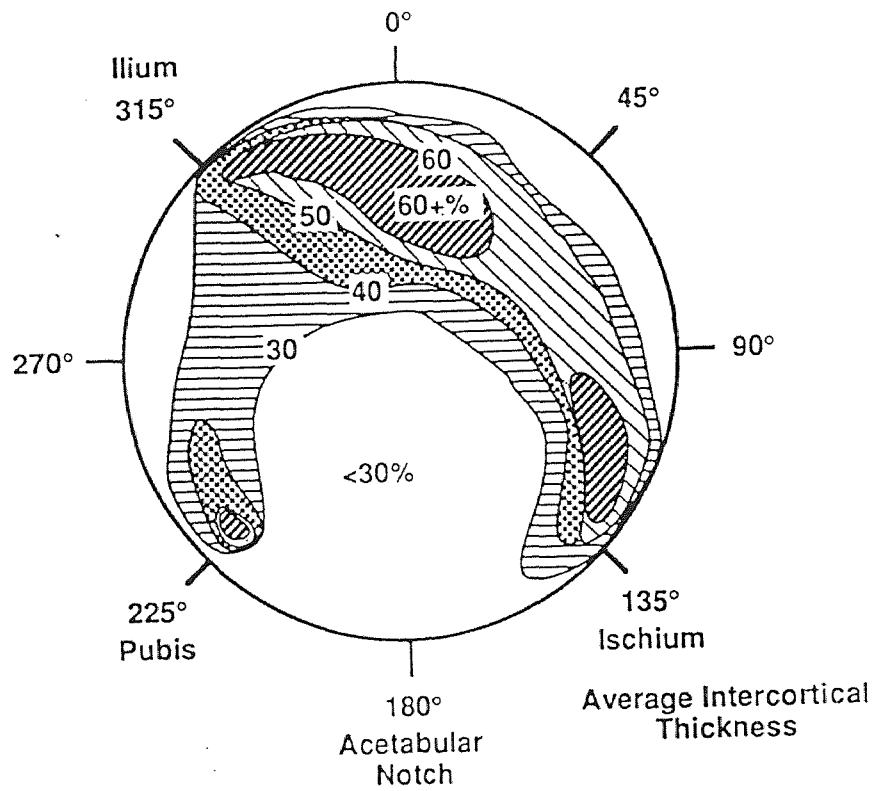


Figure 25 Average intercortical thickness mapped as a percent of acetabular diameter [37]

parallel to the rim of the acetabulum. Contact radiographs were analyzed for each section to show the regional variation of bone density. The distribution of strength and stiffness of the cancellous bone was predicted from their known relationship to bone density.

A consistent pattern was observed in the properties of the cancellous bone within the pelvis. Areas of low density and hence, inferior fixation strength, were present in the pubis and ilium superior to the lateral acetabular margin. Regions of bone suitable for unicortical fixation were found in three major areas: medial to the acetabular rim, within the body of the ischium, and within the dome of the acetabulum.

The objective of the next part of Noble's study was to determine the maximum length of screws which could be used in the acetabulum without penetrating the inner cortex. Pelves were sectioned into wedges which joined at the center of the acetabulum. The distance from the subchondral plate to the inner surface of the acetabulum was measured. To model normal orientation of bone screws, the thicknesses were taken along axes which passed through the center of the acetabulum and perpendicular to the subchondral plate.

Using these measurements, boundaries were established corresponding to safe placement of screws 10-25 mm long. Noble found that once the length of the screw exceeded 40% of the acetabular diameter, only one-quarter of the acetabulum was thick enough for screw placement. The "safe" zone for

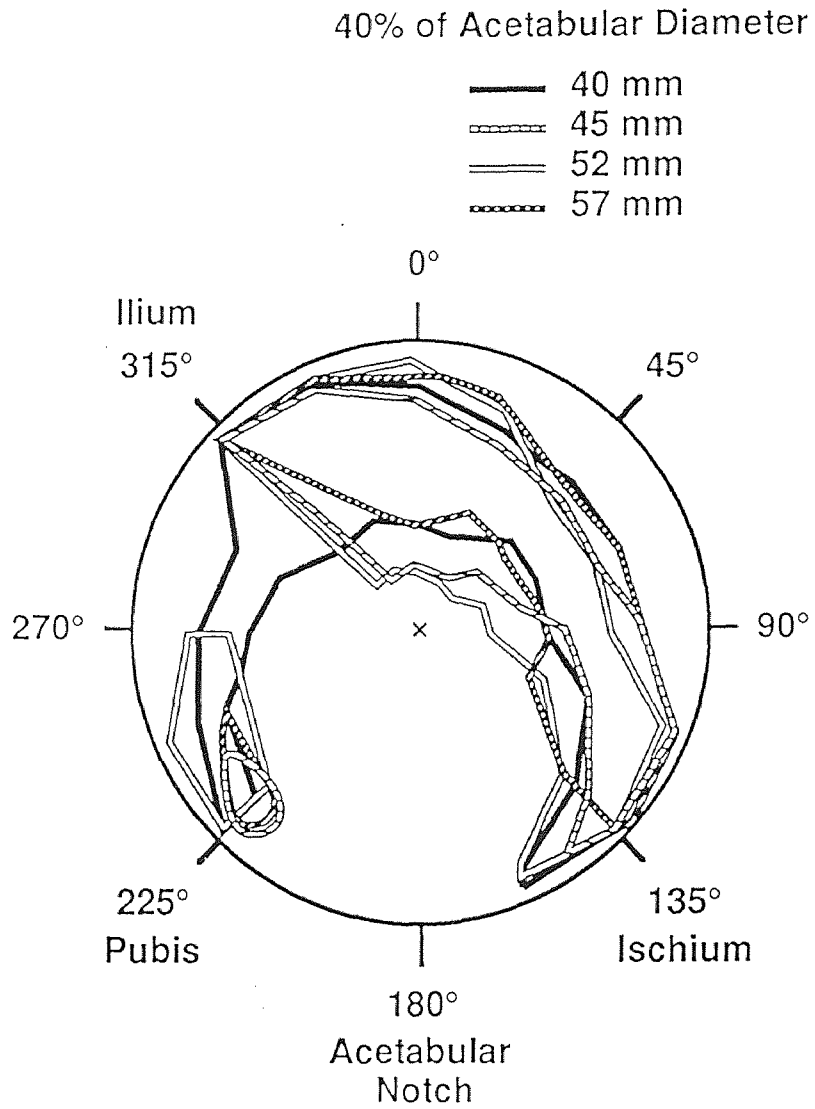


Figure 26 Safe zones at screw lengths 40% of acetabular diameter for 40, 45, 52, and 57 mm diameter acetabuli [37]

screws placed perpendicular to the subchondral plate extends in an arc from the ilium around the posterior rim to the ischium. If screws are inserted perpendicular to the acetabular rim, the "safe" zone forms a continuous arc from the ischium to the ilium to the pubis.

Noble concluded that the length of screws should be limited to 40% of the acetabular diameter while screw placement must be restricted to the posterior side of the ilio-ischial axis. These guidelines for unicortical fixation of screws will help prevent perforation of the inner cortex and therefore, protect vital structures.

Wasielowski, *et al.* [53] also examined safe placement of acetabular screws. They investigated transacetabular fixation, though. The posterior superior and posterior inferior quadrants were determined to contain the best bone stock and are relatively safe for bicortical fixation. The anterior half of the acetabulum should be avoided since the external iliac artery and vein, plus the obturator nerve, artery, and vein lie just below the bone there and would be at risk.

Another anatomic study was performed by Keating, *et al.* [26]. The anterosuperior quadrant was identified as the most dangerous area for screw placement because of the thinness of the acetabulum and the intra-abdominal vascular structures in that area. In addition, they cautioned that anatomic variations or abnormalities may extend the danger zone.

Mendes, et al. [33] issued a case report in which one of the screws inserted through an acetabular component into the pubis protruded through the medial wall. The external iliac vein was lying on the sharp point of the screw. Although the screw did not penetrate the vessel upon insertion, it was apparent that this could easily happen. Also, with time, erosion of the vessel by the screw would have taken place. The surgeons concluded that round edge screws and threads would be a safer alternative to sharp designs, and that judicious placement of the screws and attention to their length are important considerations when reconstructing the acetabulum.

5.4 Threaded Cup

5.4.1 Design Rationale

Long term complications in THA, including loosening and bone resorption, often appeared to be related to the mechanical properties of PMMA, the high coefficient of friction and unbalanced stresses on the acetabulum, and lack of sound biological fixation. To combat these problems the threaded cup was developed. In theory, threading achieves a tighter embedding in the pelvic bone than a press-fit. However, the indications are limited by bone quality and the anatomic condition; living, non-sclerotic bone and mechanical stabilization on four points of the acetabular circumference between both acetabular columns are required. One benefit of the threaded ring, designed to be thinner and less cumbersome than a full hemispheric component, is that it avoids excessive reaming for implanting the component while achieving a tight, stable fit. A comparative study of threaded components performed at UCLA indicates that the quality of initial fixation is proportional to the amount of bone engaged within the thread. Also, the amount of the ring which is threaded and the widest depth of the flange are influential [30].

5.4.2 Clinical Results

In France, Lord *et al.* [31] have used the threaded ring for at least fourteen years in more than 3000 cases. Of 118 cups followed for a ten year period, 82.2% still have satisfactory results, and can attest to the permanence of bony anchoring

with this design. Also, several of their retrieval samples confirm that bone remodelling occurred around the threaded flanges.

Dr. Bernoski [1] of the Netherlands performed a prospective study of a hemispheric self-tapping component in 1984. Over three years he implanted 202 cups. The technique Bernoski employed to implant the cups was similar to that of a thread tapping device. Insertion proceeds, with an occasional counter-clockwise return, until there is firm contact between the implant and the acetabular wall. In this manner, thread engagement is coupled with press-fit for primary fixation. Bernoski used the following as indications for the component: primary and secondary osteoarthritis and revision arthroplasty, provided that the acetabular rim was intact. The mean preoperative hip score in this study was 50. At three years follow-up, the mean score was 92.1; at six years, it rose to 92.4. Age influenced the score; patients between 40 and 50 years old had lower scores while patients between 60 and 70 had the highest mean score. Bernoski attributes the successful results to his surgical technique.

The threaded cup is not as popular in the United States. Two main objections raised against it are difficulty in implantation and the possibility of delayed migration with potential cut-out. Engh, Griffin, and Marx [12] followed 130 cups of two different hemispheric threaded designs for an average of 3.9 years. The short-term results were

disappointing; 21% of the patients showed radiographic signs of instability, while another 25% had clinical symptoms.

Emerson *et al.* [11] also had poor results using the threaded cup in revision arthroplasty. Of thirteen components implanted for an average of forty months, eight migrated with some graft resorption, five had significant radiolucent zones, and four were revised for looseness. Of particular note was the fact that the cups tended to be implanted quite vertical, probably due to the need to secure some purchase in the remaining acetabular rim. They concluded that although this was a small series in bone poor acetabula, the threaded cup was unreliable.

Hydroxyapatite coating (discussed in detail in chapter 6) appears to have a favorable effect on threaded acetabular components, as presented by Rudolph Geesink, M.D., Ph.D. [15]. He compared the results of non-coated cups to the identical design with HA coating. The addition of HA to the threaded cup improved clinical results and roentgenographic apposition to a statistically significant degree. Although acetabular bone takes some time to develop, at two years 55% of the HA coated cups had clear evidence of bone contact against the coating. Radiolucent lines were absent around the HA coated parts of all cups and no migration was recorded. The conclusion was clear that HA improved the fixation and clinical performance of threaded acetabular implants.

Nonetheless, threaded acetabular components have not

regained any popularity in the domestic market. With the excellent clinical results and easy surgical technique for cementless hemispheric implants it is unlikely that the threaded ring in its current design will be adopted again.

CHAPTER 6

HYDROXYAPATITE

6.1 Description

The application of bioactive ceramic materials in orthopedic surgery is still evolving and there is much debate on the topic. Animal studies of implant fixation have shown that coatings of these materials provide early and strong fixation to bone [28].

Bioceramics of aluminum oxide and calcium phosphate are used in a wide range of surgical applications. Aluminum oxide, hydroxyapatite (HA), and tricalcium phosphate (TCP) elicit significantly different tissue reactions due to their specific physical, mechanical, and biologic properties. In general, aluminum oxide is inert, or minimally reactive; HA is bioactive; and TCP is active, or biodegradable. The application of these bioceramics is based on their characteristics. Aluminum oxide is appropriate for structural forms which require high resistance to mechanical forces and wear. HA is used when biocompatible bonding to the tissue is desired. TCP is intended to influence tissue reactions for a finite time period, then biodegrade.

There are three general physical forms of bioceramics for biomedical applications: solid and porous particles, solid blocks, and coatings. Emphasis has been on the latter for orthopedic devices, since these produce composite surfaces on prostheses.

6.2 Processing Factors

With respect to HA coated implants, it is important to produce a uniform coating with controlled properties and a good bond strength to the substrate. Most coatings today are applied by a plasma spray technique. One implant manufacturer employs vacuum low pressure plasma spraying to apply HA to their implants [56]. In this process, an electric DC arc is struck between two electrodes while a stream of gas passes through the arc. The gases turn into a high-temperature, high-speed ionized mixture called a plasma. When the HA powder is fed into the plasma, the semi-molten particles solidify on impact with the substrate, in this case a metal implant. The entire process takes place inside a vacuum. Advantages over air plasma sprayed coatings include purer, denser coatings which exhibit increased stability and higher adhesion strengths. The HA coatings on most implants currently marketed are approximately 50 microns thick. Thicker coatings are subject to fatigue failure due to the brittle nature of HA.

The porosity of the coating also influences the mechanical properties of HA. Pores are flaws in the material, representing places where dissolution can initiate and then propagate through the material. Less porous coatings remain stable longer.

Of course, the purity of the HA powder itself is critical in determining the quality of the coating. The chemical characterization of the compound is important - the HA must be

as pure as possible to perform its bioactive function. All calcium phosphate compounds other than HA are "contaminants" and must be minimized.

HA particle size, density, and shape must also be optimized. Small particles may undergo a composition change during the coating process. For example, HA will become tricalcium phosphate which is bioresorbable. On the other hand, a large particle will not lend itself to ideal processing parameters. It may not soften enough to adhere to the substrate.

6.3 Clinical Results

Geesink [15] reported on 100 consecutive cases of total hip arthroplasties using HA coated threaded cups and femoral components. The average Harris hip score after one year was 96 out of 100 points, and after two years, 98 points. Analysis showed that pain was low immediately after surgery and only 4% at one year postoperatively. X-rays revealed a rapid bony integration of implants with bone apposition on the coating within six months. There were no radiolucent lines seen, and no implants were revised for loosening, even in the younger patients with high activity levels. At the two year mark, 55% of the acetabular components showed evidence of bony ingrowth. Geesink reported that the speed of recovery and performance of HA coated devices appeared similar to cemented components due to the early, strong, and reliable osseointegration of the implants. He is optimistic about

future performance but continued follow-up will reveal whether these excellent results can be maintained.

Drucker *et al.* [9] described their early clinical and roentgenographic results of a prospective study of HA coated stems and cups in 52 patients. At one year pain was very low and over 82% of the patients could ambulate unlimited distances without support or a limp. No radiolucent or radiodense lines were seen adjacent to the prostheses, and no cups or stems migrated. They believe that HA will help provide rapid and enhanced fixation of implants, resulting in excellent clinical results.

Since HA coated prostheses have only been FDA approved for sale in the United States for less than two years, it will be some time still before their value can be clinically assessed on a wide scale basis. Acetabular components must be evaluated over long periods to determine their ultimate success rate. The potential benefits of hydroxyapatite seem extraordinary; however, implant design and surgical technique may be overriding factors in the success of this new technology.

CHAPTER 7

ACETABULAR DEFICIENCIES

7.1 Classification Systems/Operative Techniques

One of the most important principles of reconstructing the hip concerns restoring the biomechanics of the joint. Failure to do so could lead to excessive forces on both sides of the joint, thereby contributing to mechanical failure. Other goals include obtaining acetabular continuity and integrity, to provide prosthetic and graft containment.

To facilitate planning and treatment of cases requiring acetabular reconstruction, the American Academy of Orthopaedic Surgeons Committee on the Hip developed a widely accepted system for classifying acetabular deficiencies [6]. This classification system is simple and applies to both primary and revision cases.

The classification system begins with two basic categories: segmental and cavitory. A segmental, or rim, deficiency (Type I) is any complete loss of bone in the supporting hemisphere (including the medial wall) of the acetabulum. These deficiencies are further broken down into peripheral, which are located as superior, posterior, or anterior, and central, which is medial. A medial segmental defect describes the complete absence of a portion of the inner medial wall or rim.

Cavitory defects (Type II) represent a volumetric loss in bony substance of the acetabular cavity including the medial

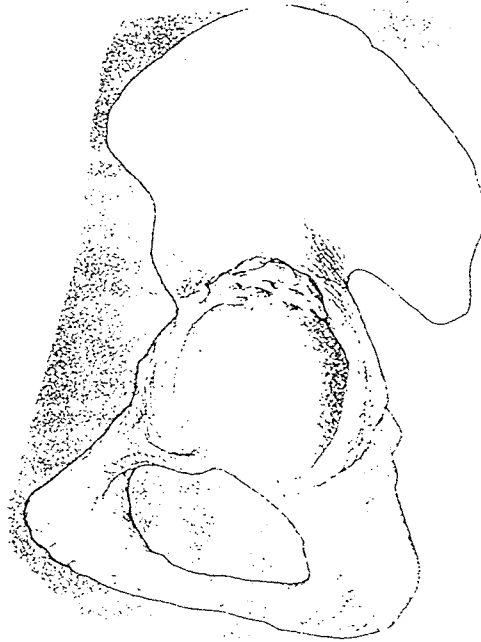

Figure 27 Superior segmental defect [6]

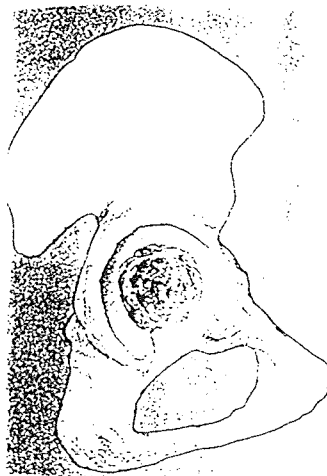


Figure 28 Central cavitory defect [6]

wall, while the acetabular rim remains intact. Cavitory deficiencies are also further classified as peripheral (superior, posterior, or anterior) and central (medial wall intact). A medial cavitory defect implies excavation of the medial wall without violation of the medial rim.

Any of these defects may exist alone or in combination. Coexisting segmental and cavitory deficiencies, Type III, are common in certain conditions. For example, a superior segmental deficiency and a superior cavity deficiency frequently both appear in congenital hip dysplasia or with superior medial migration of a prosthesis. Similarly, superior and posterior segmental deficiencies along with posterior and superior cavitory defects are identified in revision cases where osteolysis and socket migration have occurred.

A type IV deficiency is a pelvic discontinuity. This is a defect across the anterior and posterior columns with total separation of the superior from the inferior acetabulum. To complete the classification system, arthrodesis is included as the fifth type of deficiency. Actually, arthrodesis does not refer to any bony deficiency of the acetabulum, rather it identifies the condition where locating the true acetabulum is technically challenging due to a fused joint.

This classification system by the AAOS Hip Committee aids in determining operative techniques for deficient acetabula. Typically, for segmental defects, solid bulk graft

reconstruction is essential for prosthetic support; particulate grafting and/or bone cement will not give enough structural integrity.

Cavitary deficiencies, in contrast, may be managed with either solid or particulate grafts, cement, or a custom prosthesis. Since the walls of the acetabulum are intact in these cases, they provide prosthetic support so only filler material is required in the defect.

The treatment of combined defects requires reconstruction of the segmental deficiency first, then the cavitary defect may be addressed. In the case of pelvic discontinuity, the superior and inferior pelvic segments must be stabilized with plates, a bone graft, and screws before proceeding with repair of the segmental, and, finally, cavitary defects.

A systematic approach to treatment of the failed acetabulum was adopted by Paprosky, *et al.* [39]. They classified commonly encountered patterns of bone loss into three major types of defects with corresponding subtypes, and established modes of treatment for each.

The rim of a Type 1 acetabulum is almost totally supportive with no significant defects. Only particulate graft is used since structural support allografts are not necessary.

In Type 2 defects the hemisphere has been distorted. There is some bony lysis of the walls or dome, but the rim is still capable of supporting an implant. The type 2 acetabulum

is subtyped at the time of surgery. A Type A reconstruction is performed when a component touches the anterior and posterior rims but does not contact the superior rim. Several options are available for reconstruction: 1) Place the component in a "high" position where superior contact occurs. 2) Use particulate graft to fill the defect, impacting the implant against the graft. 3) Rigidly fix a femoral head allograft that matches the defect into the acetabular cavity.

A Type 2B defect means the superior rim of the acetabulum is absent. Treatment options 1 and 2 from above also apply in this case. Alternatively, a femoral head allograft may be cut in the shape of a number 7. The long portion is placed outside the acetabulum, and the short portion inside, with the angle buttressed against the ilium.

Protrusio acetabula encompass Type 2C defects. Usually particulate graft fills the defect; if the condition is severe, bulk slice allograft is used. Protrusio shells are discussed in detail at the end of this chapter.

Type 3 defects demonstrate severe bone loss with osteolysis. Rim support is inadequate due to anterior and posterior column deficiencies. Type A bone loss extends from ten o'clock to two o'clock with between two-thirds and half of the rim being present. Structural allograft is cut into a number 7 and screwed to the ilium. After reaming, the defect is treated as in 2C reconstruction. In Type B defects there is bone loss from nine to five o'clock and at least 50% of

Table 4 Scheme for treating acetabular defects [39]

| Defect | Grafting Pattern | Method of Fixation |
|---------|--|--------------------------------------|
| Type 1A | particulate graft | n/a |
| Type 2A | particulate graft and/or femoral head allograft | femoral head fixed inside acetabulum |
| Type 2B | number 7-cut femoral head allograft | outside acetabulum screws |
| Type 2C | particulate graft/cross-section wafer cut femoral head allograft | n/a |
| Type 3A | number 7-cut distal femoral condyles or proximal tibia allograft | outside acetabulum screws or plates |
| Type 3B | femoral head and proximal femur arc graft | plates |

the rim is absent. One option is to cut the proximal femur into an arc to circumferentially reconstruct the area. The graft is plated onto the ilium and ischium. All Type 3 treatments require the use of large diameter bone screws to promote initial stability of the implant/graft construct.

During the eight years of their study, Paprosky *et al.* saw few cases which did not fit into this scheme. With strict adherence to the guidelines outlined in table 4, their results have been satisfactory. No significant graft resorption or migration occurred, and little failure of the implant and allograft construct was reported.

7.2 Protrusio

Protrusio is the condition in which a gross deficiency of the medial acetabular wall exists. Several authors have set up systems to grade protrusio problems. Sotelo-Garza and Charnley [48] based their system on the medial migration of the femoral head past Kohler's line. Grade I was a protrusio from 1 to 5 mm, grade II was 6 to 15 mm, and grade III was greater than 15mm. Ranawat *et al.* [41] also classified protrusio according to Kohler's line. Type I was less than 5 mm, type II was greater than 5 mm with an intact medial wall, and type III was greater than 5mm with a defective medial wall. Ranawat and Zahn [42] based protrusion on the superior or medial migration relative to the anatomic triangle outlined by the normal acetabulum.

7.2.1 Protrusio shell

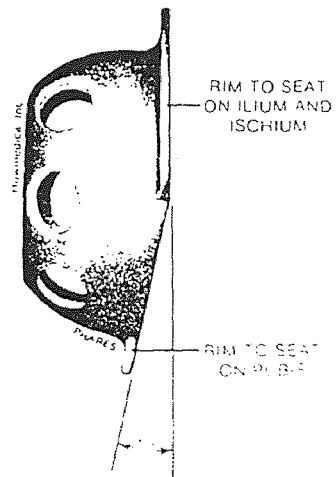



Figure 29 Two views of the Oh-Harris protrusio shell [19]

In patients with protrusion of the acetabulum due to failed cup arthroplasty, failed femoral hemiarthroplasty, or natural causes such as Paget's disease and rheumatoid arthritis, prosthetic reconstruction is challenging. Several approaches have been reported as successful. Sotelo-Garza and Charnley [48] prefer using standard acetabular components with cement packed medially in the acetabulum. Others use a metal ring to support the prosthetic socket laterally; for example, Harris and Oh [19] designed a protrusio shell to protect the medial wall from typical stresses on the hip joint.

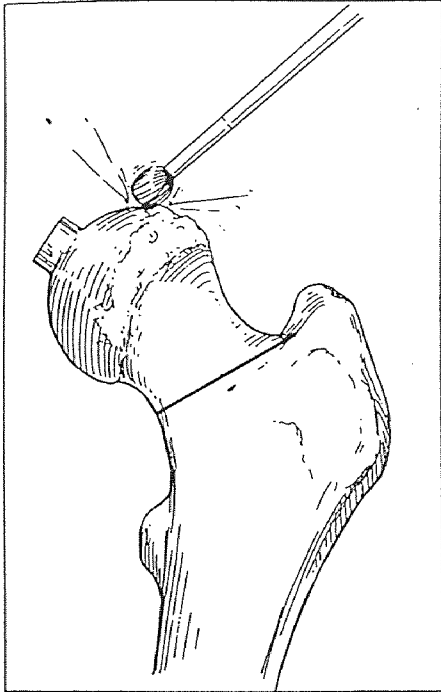
The basic concept of the protrusio shell is to provide a means of achieving stable fixation of the acetabular component in the presence of gross deficiency. To do this, the medial wall must be protected from normal stresses. This is accomplished by flanges on the shell which rest on the acetabular margins. The medial thrust is thereby transferred from the medial wall to the ilium, ischium, and pubis.

The Oh-Harris protrusio shell design was based on anatomic features and surgical factors. The flange which rests on the pubic bone is displaced 15 degrees medially from the others for solid bony contact. Also, a space is provided for the iliopsoas to exit the pelvis and cross the medial acetabular margin. This avoids psoas bursitis and damage to the psoas tendon.

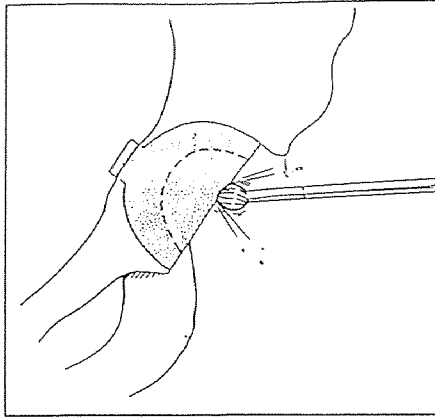
Another crucial design feature for proper function after hip replacement is the ability to position the acetabular

Facing 57

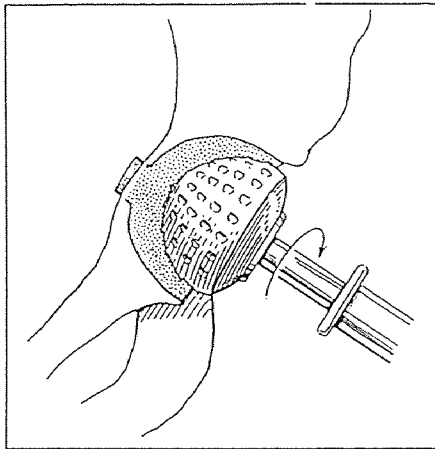
Removal of articular cartilage from the femoral head and resection of the head through the neck in the standard fashion.



Removal of the central portion of the graft to make reaming easier.



Reaming of the graft with the cheese grater reamers.



Seating of the acetabular component onto the graft to recreate the medial wall.

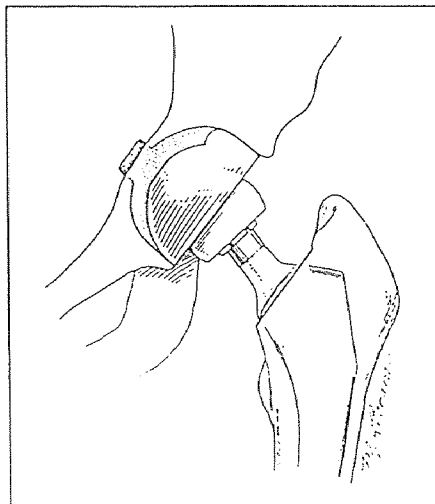


Figure 30 Heywood technique [10]

component independently of the protrusio shell since the attitude of the anatomy could lead to instability. The Oh-Harris shell is a distinct metal piece, which is cemented into the acetabulum. A separate acetabular component is then seated into the shell.

7.2.2 Surgical Technique

The surgical technique used to prepare the acetabulum for this prosthesis is basically that described by Heywood [22] in 1980 for reconstructing the protruded acetabulum. The femoral head is resected in normal fashion. Following dislocation of the hip, a pilot hole is drilled in the acetabular floor at 20 degrees above horizontal. A deepening reamer is then used to prepare a bleeding bed for the autograft. The resected head is sculpted with a high speed burr to create a protrusion 5 to 10 mm high, the same width as the pilot hole. The graft is pressed into the acetabulum and reamers are then used to create a concentric socket. The prosthesis of choice, including the Oh-Harris Shell can be implanted into this prepared acetabulum.

Ebert et al. [10] decide intraoperatively which prosthesis to use. Provided that at least 50% of the cup is seated on host bone, a porous-coated implant is selected; cement is used, otherwise. In their series of 35 acetabular protrusio cases, there were no component failures and no bone graft resorption. All autogenous grafts were incorporated into host bone by 1 year post-surgery. As in other long-term

follow-up studies [22,42], normalization of the head acetabular relationship by lateralizing the cup eliminated the progression of protrusio in this study.

7.2.3 Finite Element Analysis

Similar results were predicted in a finite element study by Crowninshield, *et al.* [5]. They proposed that the response of bone in the acetabular region to prosthesis-induced alterations in the stress distribution there may contribute to component loosening. To investigate possible mechanical factors in loosening of the acetabular component in protrusio acetabuli, they created an axisymmetric model of the bone. Five component designs were evaluated: polyethylene, metal-backed, protrusio rings, protrusio cups, and a metal medial acetabular shell. Two surgical techniques, normal and medial placement of the cup, were reviewed for each. Stress levels and distribution were predicted in all cases for the component, cement, and the bone. Since this model is not an exact representation of hip reconstruction, the results are most useful for comparing the stress states for different prostheses and techniques.

Basically, Crowninshield *et al.* showed that normal placement of the cup results in lower stress levels in the medial bone around the protruded area than those seen with medial placement of the cup. The addition of metal backing to the implant, or the addition of a protrusio cup, further reduces these stresses, and may prevent medial migration of

the prosthesis. Protrusio rings and shells appear to have little effect on the stresses in the medial pelvic cortex. Their conclusion was that if loosening and migration of the acetabular component are related to the development of high stresses in the surrounding bone, lateral placement of a metal backed cup should reduce the incidence of loosening in protrusio acetabuli.

7.3 Bone Grafting

7.3.1 Types

As discussed, bone grafts are often used in the reconstruction of failed total hip arthroplasties. The grafts serve one or both of two purposes, as a source of osteogenetic cells and as a mechanical support. Autogenic bone, that from the patient or a direct family member, performs best, but because of limited supply, allogeneic bone often must be used. Allografts of bone, those from foreign donors, elicit transplantation immunity which may contribute to the higher failure rate seen with these grafts. Attempts to reduce the immunogenicity of allograft bone have led researchers to freeze-drying the material; failures still occur one-quarter of the time the allografts are used. Goldberg and Stevenson [16] studied the biologic response to bone autografts and allografts to obtain a better understanding of what contributes to a successful graft.

Basically, the outcome of the graft is determined by specific properties of bone, both cortical and cancellous.

Foremost is osteogenesis: the synthesis of new bone by host or graft cells. New bone from the graft is produced by the surface cells of properly handled fresh bone grafts. Cancellous bone has a larger surface area of cells and therefore a greater potential for producing new bone than cortical bone. New bone from the host is produced through the process of osteoinduction - mesenchymal cells from the host differentiate into osteoblasts which lay down bone. The process of osteoconduction will also occur. Osteoconduction is growth of the capillaries, perivascular tissue, and osteoprogenitor cells of the host into the graft. The graft serves as a trellis for the ingrowth of these tissues.

In addition to biologic functions, the graft may provide structural support until the recipient tissue can bear weight. Cortical bone grafts will commonly provide structural integrity during remodeling.

The incorporation of all types of grafts occurs by creeping substitution. This is the gradual resorption of the grafts with replacement by new bone. Bone graft incorporation is characterized by five distinct stages. Cortical and cancellous grafts initially invoke an inflammatory response. Next is vascularization of the graft, followed by osteoinduction. The fourth stage of incorporation is osteoconduction; it may last for several months in cancellous autografts, but could persist for years in cortical autografts or allografts. Finally, the graft is remodeled, as influenced

by mechanical loads seen by the graft, and becomes a supporting structure. Although the graft will function effectively, it may still contain a significant amount of nonviable tissue. Typically, cancellous grafts are fully resorbed and replaced by host bone, but this may never happen with cortical grafts.

7.3.2 Clinical Results

Goldberg and Stevenson's canine studies supported these principles. Autogenic bone grafts provided the most efficient structure for reconstruction of bony defects. Allograft function appeared to be inhibited in the revascularization phase which may be immunologically mediated. Their laboratory findings suggest that histocompatibility matching may significantly improve the success of frozen allograft bone.

The results of grafts in total hip arthroplasty have been successful in some cases, failures in others. Deficiency of the medial acetabular wall is a difficult problem in total hip arthroplasty. It is commonly encountered in patients with central fracture dislocations with nonunions and protrusio. Mendes *et al.* [34] believe that any lasting reinforcement should be biological since mechanical support is unreliable. Massive bone grafts carry the risk of mechanical weakening due to creeping substitution just when a strong buttress is needed. They prefer to reconstruct the acetabular wall with chips of autologous cancellous graft which have a strong potential for osteogenesis and are affected biomechanically by

creeping substitution.

Mendes *et al.* reconstructed the acetabulum of eight patients with autologous chips of bone graft. Wire mesh was implanted over the graft to prevent the flow of cement into the chips. The acetabular component was then implanted immediately following cement injection. Clinical results are encouraging. The grafts were incorporated into the acetabular bone within six to ten months. At two to six year follow-up, seven patients maintain moderate to full activity.

The use of bulk graft was explored by Mulroy and Harris [36]. Autogenous grafting with corticocancellous bone from the femoral head was introduced for patients with severe acetabular deficiencies. The initial results of these grafts combined with cemented prostheses were promising and at seven years postoperative, all of the grafts had united to the ilium. However, at an average of 11.8 years after the initial surgery, 20% required a second operation for failed acetabular fixation. Another 26% showed definite radiographic signs of loosening, bringing the total failure rate to 46%. The loss of structural integrity of the graft superiorly or superolaterally appeared to be the most common mechanism that initiated the failures.

Mulroy and Harris no longer recommend the use of bulk grafts for cases of severely deficient acetabular bone stock. Today they use titanium fibermesh hemispheric acetabular components fixed in with screws. Because no cement is needed,

a small cup can be used and will be completely covered in most patients. They believe that with 70% coverage by host bone, the implant will be stable and allow adequate ingrowth of bone. In rare cases of extreme deficiencies, bulk autogenous graft will be used with cemented components, but care must be taken to obtain posterior and superior support from the graft.

A staged approach to arthroplasty, with preliminary construction of adequate bone stock to accommodate the acetabular prosthesis was evaluated by Solonen *et al.* [47]. In stage one, they managed their patients with large defects and poor quality surrounding bone with well vascularized pedicular autogenous grafts. Well vascularized grafts are a source of osteogenic cells and reduce the risk of postoperative infection since blood circulation becomes adequate. Free bone grafts, on the other hand, are essentially nonviable tissue suitable for small defects in already well vascularized sites. They eventually become reossified by creeping substitution of host bone.

Once ample bone stock is seen, stage two, implantation of the prosthesis, may commence. The interval between the stages must not be too long, though, because the transposed bone will atrophy if kept nonfunctional for a long time. Solonen *et al.* have produced good results with this technique at an average follow-up of 31 months.

7.3.3 Revision

Grafts are quite often used in revision cases. Emerson *et al.*

[11] used nonstructural morselized fresh-frozen allograft or segmental freeze-dried allograft in 106 acetabular revisions. Three types of acetabular components were implanted. Evaluation after 12 to 56 months revealed that the titanium porous coated press-fit component had little migration, reliable graft healing, no revisions, and better clinical scores than the other two designs. The morselized allograft performed better under stable cups while the large segmental grafts did well when combined with buttress plating and screw fixation.

Twenty-four cementless total hip arthroplasties were performed and analyzed by Convery *et al.* [4]. Thirteen autografts and 11 allografts were used; the average follow-up was 34 months. The autograft augmentations were uniformly successful. Two fixation failures occurred in the allograft group. Resorption was also greater in this group, and was severe in the two reported failures. Although less successful in their series, Convery *et al.* believe that there is a place for frozen allografts. They note that the acetabular deficiencies were extreme in these cases and, in practice, autograft material is less available.

In Japan, Itoman *et al.* [25] also employed allograft bone for reconstruction of acetabular defects in revision cases. Since the pelvic bone is usually in poor condition, they used a metallic supporting device to ensure primary fixation of the graft to the host. The position of the acetabular component

was maintained when the device was used. Without the supporting structure, results were far less favorable. They concluded that allograft reconstruction was a beneficial procedure provided that a metallic supporting device was installed for reinforcement.

CHAPTER 8

CONCLUSION

It has been more than three decades since Sir John Charnley's pioneering efforts introduced successful cemented total hip arthroplasty. Many of the clinical results derived from Charnley's technique, using a cemented polyethylene acetabular prosthesis, have been satisfactory, even after 25 years of follow up.

Metal backing was added to the all polyethylene component for a more even distribution of stresses in the bone, cement, and prosthesis in an effort to decrease the incidence of cup failures due to loosening. However, this design change was primarily based on theoretical finite element analyses, and clinical results have not clearly demonstrated any advantage. Current cost pressures will likely push the trend back towards thick, all polyethylene sockets.

In an effort to find better, longer lasting fixation of the implant to the bone, especially for young, active, or heavy patients, cementless prostheses were developed. Cups with roughened surface textures and ingrowth potential were designed to enhance the bone to implant interface.

Cementless acetabular implants, with the exception of the threaded cup, have been quite successful. It appears that they will maintain or increase their popularity, especially since the surgical technique is quicker, easier, and more conservative than using cement. The use of screws or other

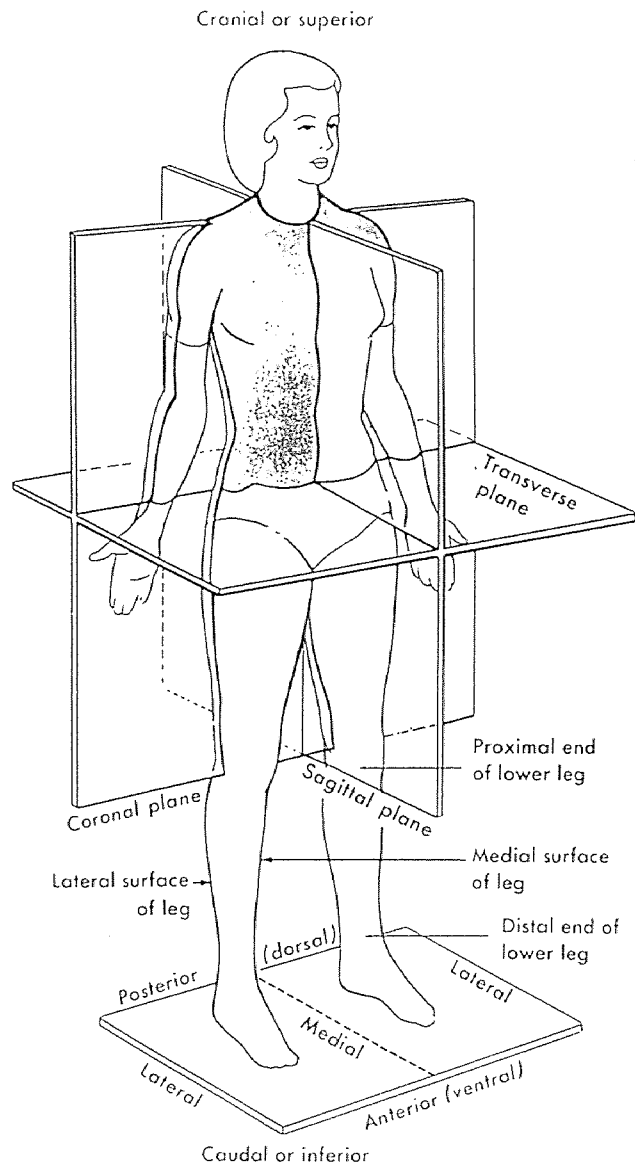
adjuvant fixation is a controversial topic. Some believe that the benefit of increased initial stability is outweighed by the potential problems of screw backout, wear debris generation, and puncturing of vital structures.

The use of hydroxyapatite on acetabular prostheses to stimulate earlier ingrowth by increasing the affinity of bone to the coated surface is still in its infancy. Early results are encouraging, but long term follow up is critical in determining the success of implanted sockets. Of course, HA coating raises the price of the prosthesis, so the orthopaedic community is waiting to determine if the cost-benefit ratio of this technology will be favorable.

Improvements are still needed for treating deficient sockets. Systems to classify and reconstruct the atypical acetabulum have been employed with some success. However, these cases, including revision of a failed component, are often complex and unpredictable. Cups with add on wedges for customization to the patient are on the horizon.

Overall, total hip arthroplasty is a highly effective procedure for pain relief and restoration of the patient's mobility. It is, nonetheless, a procedure in which improvements are always sought and needed. The future holds endless possibilities and promise for increased clinical success.

APPENDIX Anatomic Positions and Directions [57]



REFERENCES

1. Bernoski, F.P., "Experience with a Hemispheric Threaded Acetabular Component," presented at State-of-the-Art In Total Joint Replacement, Scottsdale, 1990.
2. Carter D., Vasu R., and Harris W., "Stress Distribution in the Acetabular Region - II. Effects of Cement Thickness and Metal Backing of the Total Hip Acetabular Component," J. Biomechanics, 1982, Vol. 15 No. 3, pp. 165-170.
3. Collier J., Mayor M., Chae J., Surprenant V., Surprenant H., and Dauphinais L., "Macroscopic and Microscopic Evidence of Prosthetic Fixation with Porous-Coated Materials," CORR, 1988, No. 235, pp. 173-180.
4. Convery F., Minteer-Convery M., Devine S., and Meyers M., "Acetabular Augmentation in Primary and Revision Total Hip Arthroplasty with Cementless Prostheses," CORR, 1990, No. 252, pp. 167-175.
5. Crowninshield R., Brand R., and Pedersen D., "A Stress Analysis of Acetabular Reconstruction in Protrusio Acetabuli," Journal of Bone and Joint Surgery, 1983, Vol. 65-A No. 4, pp.495-499.
6. D'Antonio J., Capello W., Borden L., Bargar W., Bierbaum B., Boettcher W., Steinberg M., Stulberg S., and Wedge J., "Classification and Management of Acetabular Abnormalities in Total Hip Arthroplasty," CORR, 1989, No. 243, pp.126-137.
7. DeLee J. and Charnley J., "Radiological Demarcation of Cemented Sockets in Total Hip Replacement," CORR, 1976, No. 121, pp. 20-32.
8. Dorr L. and Takei G., "Review of Total Hip Arthroplasties in Patients 45 Years and Younger," presented at the Annual Meeting of the American Academy of Orthopaedic Surgeons, Las Vegas, Nevada, 1981.
9. Drucker D., Capello W., D'Antonio J., and Hile L., "Total Hip Arthroplasty Using a Hydroxyapatite Coated Acetabular and Femoral Component," Orthopaedic Review, 1991, Vol. 20 No. 2, pp. 189-190.
10. Ebert F., Hussain S., and Krackow K., "Total Hip Arthroplasty for Protrusio Acetabuli: A 3- to 9-Year Follow Up of the Heywood Technique," Orthopedics, 1992, Vol. 15 No. 1, pp.17-20.

11. Emerson R., Head W., Berklacich F., and Malinin T., "Non-cemented Acetabular Revision Arthroplasty using Allograft Bone," CORR, 1989, No. 249, pp. 30-43.
12. Engh C., Griffin W., and Marx C., "Cementless Acetabular Components," JBJS, 1990, 72-B No. 1, pp.53-59.
13. Fitzgerald R., *Non-Cemented Total Hip Arthroplasty*. Raven Press, New York, 1988.
14. Freeman M., McLeod H., and Levai J., "Cementless Fixation of Prosthetic Components in Total Hip Arthroplasty of the Knee and Hip," CORR, 1983, No. 176, pp. 88-91.
15. Geesink R., "Hydroxyapatite-Coated Total Hip Prostheses," CORR, 1990, No. 261, pp. 39-58.
16. Goldberg V. and Stevenson S., "Natural History of Autografts and Allografts," CORR, 1987, No. 225, pp. 7-16.
17. Griffith M., Seidenstein M., Williams D., and Charnley J., "Eight Year Results of Charnley Arthroplasties of the Hip with Special Reference to the Behavior of Cement," CORR, 1978, No. 137, pp. 24-36.
18. Harris W. and Maloney W., "Hybrid Total Hip Arthroplasty," CORR, 1989, No. 249, pp. 21-29.
19. Harris W. and Oh I., *Oh-Harris Protrusio Shell Surgical Technique*. Rutherford, Pfizer Hospital Products Group, 1978.
20. Harris W. and Penenberg B., "Further Follow-up on Socket Fixation Using a Metal Backed Acetabular Component for Total Hip Replacement. A Minimum Ten-Year Follow-up Study," JBJS, 1987, Vol. 69-A, pp. 1140-1143.
21. Harris W. and White R., "Socket Fixation Using a Metal-Backed Acetabular Component for Total Hip Replacement," JBJS, 1982, 64-A No. 5, pp. 745-748.
22. Heywood A., "Arthroplasty with Solid Bone Graft for Protrusio Acetabuli," JBJS, 1980, 62-B, pp. 332-336.
23. Huiskes R., *Some Fundamental Aspects of Human Joint Replacement*. Netherlands, University of Nijmegen, Rik Huiskes, 1979.
24. Hungerford D., Haberman E., Kenna R., Hedley A., and Borden L., *The PCA Primary Hip System Surgical Technique*. Rutherford, Pfizer Hospital Products Group, 1988.

25. Itoman M., Yamamoto M., Yonemoto K., and Kai H., "Radiological Evaluation on Allograft Reconstruction of the Acetabulum Combined with Supporting Device in Revision Total Hip Replacement," *Nippon Seikeigeka Gakki Zasshi*, 1992, 66 (1), pp. 23-30.
26. Keating M., Ritter M., and Faris P., "Structures at Risk from Medially Placed Acetabular Screws," *JBJS*, 1990, Vol. 72- A No. 4, pp. 509-511.
27. Lachiewicz P., Suh P., and Gilbert J., "In Vitro Initial Fixation of Porous-coated Acetabular Total Hip Components," *The Journal of Arthroplasty*, 1989, Vol. 4 No. 3, pp. 201-205.
28. Lemons J., "Bioceramics," *CORR*, 1990, No. 261, pp.153-158.
29. Levy R., Noble P., Tullos H., Turner R., Scheller A., and Lewallen D., *The Howmedica Precision Hip System*. Rutherford, Pfizer Hospital Products Group, 1988.
30. Lord G., Marotte J-H., Blanchard J-P., Guillamon J-L., and Gentaz R., "The Acetabular Component/ Do We Have the Solution?," presented at State-of-the-Art In Total Joint Replacement, Scottsdale, 1990.
31. Lord G., Marotte J-H., Blanchard J-P., Guillamon J-L., and Gentaz R., "A Foutreen Year Experience with the Threaded Ring," presented at State-of-the-Art In Total Joint Replacement, Scottsdale, 1990.
32. McCutchen J., Collier J., and Mayor M., "Osseointegration of Titanium Implants in Total Hip Arthroplasty," *CORR*, 1990, No. 261, pp. 114-125.
33. Mendes D., Menachem A., and Lieberson S., "Fixation Screws of the Acetabular Component in Hip Replacement," *Orthopedics*, 1992, Vol. 15 No. 2, pp. 215-216.
34. Mendes D., Roffman M., and Silbermann M., "Reconstruction of the Acetabular Wall with Bone Graft in Arthroplasty of the Hip," *CORR*, 1984, No. 186, pp.29-37.
35. Morscher E., Bereiter H., and Lampert C., "Cementless Press- fit Cup," *CORR*, 1989, No. 249, pp. 12-20.
36. Mulroy R. and Harris W., "Failure of Acetabular Autogenous Grafts in Total Hip Arthroplasty," *JBJS*, 1990, Vol. 72-A No. 10, pp. 1536-1540.
37. Noble P., "Acetabular Anatomy and the Design of

- Cementless Acetabular Cups," 1992, research submitted to Howmedica, Division of Pfizer Hospital Products Group.
38. Oh I., "A Comprehensive Analysis of the Factors Affecting Acetabular Cup Fixation and Design in Total Hip Replacement Arthroplasty: A Series of Experimental and Clinical Studies," The John Charnley Award Paper, Hip Society Meeting, AAOS 1983.
 39. Paprosky W., Lawrence J., and Cameron H., "Classification and Treatment of the Failed Acetabulum: A Systematic Approach," Contemporary Orthopaedics, 1991, Vol. 22 No. 2, pp. 121-130.
 40. Pedersen D., Crowninshield R., Brand R., and Johnston R., "An Axisymmetric Model of Acetabular Components in Total Hip Arthroplasty," J. Biomechanics, 1982, Vol. 15 No. 4, pp. 305-315.
 41. Ranawat C., Dorr L., and Inglis A., "Total Hip Arthroplasty in Protrusio Acetabuli of Rheumatoid Arthritis," JBJS, 1980, Vol. 62A, pp. 1059-1065.
 42. Ranawat C. and Zahn M., "Role of Bone Grafting in Correction of Protrusio Acetabuli by Total Hip Arthroplasty," Journal of Arthroplasty, 1986, Vol. 1 No. 2, pp. 131-137.
 43. Ritter M., "Wear Rate of Metal-Backed Cups Not Evident at First," Orthopedics Today, 1992, July, p. 19.
 44. Ritter M., Keating E., Faris P., and Brugo G., "Metal-Backed Acetabular Cups in Total Hip Arthroplasty," JBJS, Vol. 72-A No. 5, pp. 672-677.
 45. Sarmiento A., Ebramzadeh E., Gogan W., and McKellop H., "Cup Containment and Orientation in Cemented Total Hip Arthroplasties," Journal of Orthopaedic Research, 1990, Vol. 8 No. 3, pp. 448-452.
 46. Sarmiento A., Ebramzadeh E., Gogan W., and McKellop H., "Total Hip Arthroplasty with Cement," JBJS, 1990, Vol. 72-A, No. 10, pp. 1470-1476.
 47. Solonen K., Rindell K., and Paavilainen T., "Construction of Acetabular Bone Stock," Archives of Orthopaedic and Traumatic Surgery, 1988, Vol. 107, pp. 263-267.
 48. Sotela-Garza A. and Charnley J., "The Results of Charnley Arthroplasty Performed for Protrusio Acetabuli," Clinical Orthopaedics, 1978, Vol. 132, pp. 12-18.

49. Stillwell W., *The Art of Total Hip Arthroplasty*. Orlando, Grune & Stratton, Inc., 1987.
50. Sumner D., Jasty M., Turner T., Urban R., Galante J., Bragdon C., and Harris W., "Bone Ingrowth in Porous Coated Acetabular Components Retrieved from Human Patients," *Transactions of the Orthopaedic Research Society*, 1987, p. 509.
51. VanSyckle P. and Walker P., "Parametric Analysis of Design Criteria for Acetabular Components of Surface Replacement Hip Devices," *Transactions of the Orthopaedic Research Society*, 1980, p. 292.
52. Vasu R., Carter D., and Harris W., "Stress Distribution in the Acetabular Region - I. Before and After Total Joint Replacement," *J. Biomechanics*, 1982, Vol. 15 No. 3, pp. 155-164.
53. Wasielewski R., Cooperstein L., Kruger M., and Rubash H., "Acetabular Anatomy and the Transacetabular Fixation of Screws in Total Hip Arthroplasty," *JBJS*, 1990, Vol 72-A No. 4, pp. 501-508.
54. Wilson-MacDonald J., Morscher E., and Masar Z., "Cemented Uncoated Polyethylene Acetabular Components in Total Hip Replacement," *JBJS*, 1990, Vol. 72-B No. 3, pp. 423-430.
55. Wroblewski B., Taylor G., and Siney P., "Charnley Low-Friction Arthroplasty: 19- to 25-Year Results," *Orthopedics*, 1992, Vol 15, No. 4, pp.421-424.
56. -----, Howmedica Technical Monograph, "Hydroxyapatite Key Facts and Issues," 1991.
57. -----, Howmedica Sales Training Manual, "Total Hip Arthroplasty," 1989.

GLOSSARY

| | |
|--------------------|--|
| abduction | Movement away from the median plane |
| acetabulum | The cup-shaped portion of the hip joint formed by the junction of the ilium, ischium, and pubis; it serves as the socket for the head of the femur |
| adduction | Movement toward the median plane |
| anterior | Toward the front part of the body |
| arthritis | A nonspecific term describing a variety of acute or chronic joint disorders |
| arthrodesis | Surgical fusion of a joint |
| arthroplasty | Surgical reconstruction of a joint |
| articulate | The place of union or junction of two or more bones of the skeleton |
| avascular necrosis | Bone death due to lack of blood supply |
| bony ingrowth | The ingrowth of bone into the surfaces of prostheses designed for this purpose |
| bursa | A sac or sac-like cavity filled with fluid |
| bursitis | Inflammation of a bursa |
| cancellous | Lattice-like, spongy type of bone |
| capsulotomy | An incision into the joint to release a constricted or adherent joint |
| cartilage | Fibrous connective tissue |
| cortical | The thick, compact outer portion of bone |
| denude | To strip of covering |
| distal | Away from; furthest point of reference |
| endoprosthesis | Prosthesis used on the femoral side of the hip joint with no prosthesis on the acetabular side |
| fascia | A fibrous membrane covering, supporting, and separating muscles |

| | |
|-------------------|---|
| femur | Thigh bone |
| fibrocartilage | A type of fibrous, cartilaginous tissue found at relatively immobile joints |
| fossa | A furrow or shallow depression |
| frontal plane | A vertical plane dividing the body into front and back; also called the coronal plane |
| hemi-arthroplasty | Reconstructive joint surgery in which only one side of the joint is replaced |
| hypertrophy | Increase in size of structure |
| iliopsoas | Large hip flexor muscle which inserts into the lesser trochanter |
| ilium | The largest of three bones of the pelvis |
| immunogenic | producing the condition of resisting and overcoming infection |
| inferior | Towards the feet |
| in vitro | In glass, as used in the laboratory |
| in vivo | Within the living body |
| ischiofemoral | Junction of the ischium and femur |
| ischium | The U-shaped bone of the lower pelvis |
| joint capsule | Sac-like envelope, composed of fibrous tissue, which encloses the cavity of a joint |
| lateral | At the side; away from the midline |
| lavage | Washing or irrigation of a wound or cavity |
| medial | Toward, or closer to, the midline |
| necrosis | Cell death |
| osteoarthritis | Chronic disease of a joint with excessive erosion of the cartilage surface |
| osteotomy | Surgical cutting of bone |
| perineum | space between the anus and scrotum or posterior vulva |

| | |
|----------------------|---|
| posterior | Situated in back |
| process | A bony prominence or projection |
| proximal | Close to the nearest point of reference |
| pseudo-arthrosis | A "false-joint" created by abnormal callus formation |
| resection | Surgical removal of a portion of a structure |
| resorption | Bone loss through physiologic or pathologic activity |
| rheumatoid arthritis | A systemic disease characterized by inflammation of the soft tissue surrounding a joint |
| subchondral | Bone lying beneath cartilage |
| subluxation | Incomplete or partial dislocation |
| superior | Toward the head |
| vascular | Pertaining to blood vessels |